

Retrospective Evaluation of Position of Mental Foramen and Its Relationship with Gonial Angle Using Cone Beam Computed Tomography

Farzane Ostovar Rad¹, Somayeh Nemati¹, Zahra Yousefi², Nadia Manavi³

¹Assistant Professor, Dental sciences Research Center, Department of Dentomaxillofacial Radiology, School of Dentistry, Guilan University of Medical Sciences, Rasht, Iran.

²Dental Sciences Research Center, Department of Dentomaxillofacial Radiology, School of Dentistry, Guilan University of Medical Sciences, Rasht, Iran.

³Dentist, Dental Sciences Research Center, School of Dentistry, Guilan University of Medical Sciences, Rasht, Iran.

Received 29 June 2020 and Accepted 11 November 2020

Abstract

Introduction: Mental foramen (MF) appearance is quite diverse. Failure to properly diagnose and protect the nerve may result in its damage during medical procedures such as surgery and placement of dental implants. This study evaluated the position of MF and its relationship with gonial angle using cone beam computed tomography (CBCT) images. **Methods:** 128 gonial angles from 64 CBCT images were measured and divided into low-angle ($\leq 125^\circ$) and high-angle ($> 125^\circ$) categories. MF was divided into five types considering its position in cross-sectional profiles: type A (under apex of first premolar); B (under apex of second premolar); C (between first and second premolars); D (anterior to first premolar); and E (posterior to second premolar). The length of mental canal and its buccolingual and superior-inferior position was also evaluated. Independent T-test and Chi-square tests were used with statistical significance set at $P < 0.05$. **Results:** The highest frequency of MF position in the high and low-gonial angle categories was type C and the lowest in high-angle and low-angle were type E and D, respectively. The position of the foramen and measurements of the mental canal was not affected by age, gender, or gonial angle ($P > 0.05$). **Conclusion:** Position of MF was not found to be related to patients' age, sex, or gonial angles. Since a precise determination of the MF position is difficult due to its different anatomical variations and also because of potential damages during the treatment procedures in this

area, radiographic analysis and determining its location among different populations is necessary.

Keywords: Mental Foramen, Gonial Angle, Cone Beam Computed Tomography.

Ostovar Rad F, Nemati S, Yousefi Z, Manavi N.

Retrospective Evaluation of Position of Mental Foramen and Its Relationship with Gonial Angle Using Cone Beam Computed Tomography. *J Dent Mater Tech* 2021; 10(1): 44-53.

Introduction

Mental foramen (MF) is an important anatomical landmark on the outer surface of the mandible in the premolar area. Physicians should be aware of its exact location when performing local anesthesia, incision, flap lift and osteotomy in the vicinity of the MF. While performing surgical procedures, particularly, implant placement, endodontic surgery, root resection, extraction of tooth, cyst, or tumor, orthognathic surgery, and fixation of facial fractures, attention must be paid to avoid damaging the neurovascular bundle exiting in the MF (1).

Radiographically, MF can be seen as a lucent and round region on both sides of the mandible. Conventional radiography techniques widely used in dentistry, including periapical and panoramic, provide a 2-dimensional image of a 3-D structure (2,3). Thus, due to the superimposition of adjacent anatomical landmarks

(2,4-5), trabecular bone pattern (6), thinness of mandible (4-6), and being positioned below the end of the periapical film (4), MF may not be visible in certain cases.

Moreover, the opening of MF leans upward and toward back, consequently, it is not in the usual view of the premolars in the longitudinal axis of the canal opening. On the other hand, due to its position on the surface of the mandible, its location in relation to the root of the teeth is affected by the change of the angle of radiation. When the image of mental foramen falls on the apex of one of the premolars, it may mimic a periapical lesion. In such cases, the presence of a dental canal, which extends to the suspicious radiolucency or a detectable lamina dura in the mentioned area, could reveal the true nature of this overcast image. The relative thinness of the lamina dura superimposed on this lucent foramen results in a significant burn out of the former thus making the diagnosis further complicated. However, a second radiography from a different angle clearly shows lamina dura as well as the change in location of MF radiolucency in comparison to the tooth apex (7).

Nowadays, Cone beam computed tomography (CBCT) has brought advancements in dentistry. This imaging modality has enabled an accurate three-dimensional evaluation of the bony structures in the maxillofacial region (1-5), and as a result, enabling the evaluation of MF in sagittal, axial, and coronal cross sections (8).

Gonial angle (GA) is an important indicator for determining growth pattern, evaluating mandibular rotation, and deciding on extraction pattern in class II patients and an influential factor in deciding on surgery in skeletal class III patients and in forensic age estimation (9). GA is formed when Ramus line (tangent to the posterior border of ramus) and mandibular line (the line in contact with the inferior border of mandible passing gnathion) intersect each other (10).

Some reports suggest that occlusal forces are related to the shape of mandibular angle (9). A high gonial angle indicates the tendency of the mandible to rotate backward with the growth of the condyles toward the back, which is reflected by a steep mandibular plane and, as a result, the posterior orientation of growth. On the contrary, a smaller gonial angle represents the vertical growth of the condyle (11).

German and French researchers made measurements of GA in the late 19th century for the first time. Their queries showed that the average mandibular angle did not alter from adulthood until at least the age of 70, except in cases where there were extensive tooth loss (12).

There is disagreement regarding the exact position of the MF and adjacent anatomical landmarks due to their various differences (13-15). Since no study has been published to investigate the morphometric relationship of gonial angle with position of mental foramen in CBCT images, the present study aimed to investigate the location of MF and its relation with gonial angle in a group of Iranian population by using CBCT imaging.

Materials and Methods

In this analytical, cross-sectional study, in order to examine the position of MF with respect to gonial angle, 64 samples of CBCT images were collected from the archives of radiology department of dental school of Guilan University of Medical Sciences (GUMS). The total of 128 gonial angles had been collected for various reasons including orthodontic treatment, surgery, implant placement, among others. The CBCT images had been prepared using Pax-i 3D unit (Vatech, Hwaseong, Korea). Exposure parameters for each sample were as follows: 95 kVp, 5.2 mAs, 9s scan time, 0.25 voxel size, and 15×15cm FOV for mandible Mode.

Inclusion criteria were full field CBCT images that covered the entire mandible, ramus, and condyle area of both sides; patients aged 18 to 50 years, with their both premolars (number 4 and 5) and first and second molars in place. Exclusion criteria were images with involving lesions in mandibular canal or mental foramen; edentulous patients; and images of primary and mixed dentition. The present study was confirmed and approved by the ethics committee of GUMS and was assigned code of ethics 1397422.

All panoramic images were reconstructed by the same device software. All CBCT images were evaluated by student under the supervision of an oral and maxillofacial radiologist.

Using Pax-i 3D unit, reconstructed panoramic and obtained cross-sectional images, the following parameters were examined:

- 1) Measurement of left and right gonial angles in reconstructed panoramic images: Line "a" was drawn tangentially with the most prominent point of posterior border of ramus and condyle, and line "b" was tangent with the inferior border of mandible. The angle created between lines "a" and "b" was measured as gonial angle (GA) (Figure 1). Then, scans were divided into two groups according to the size of the gonial angle: Low angle ($\leq 125^\circ$) and high angle ($> 125^\circ$) (16). (Figure 1)

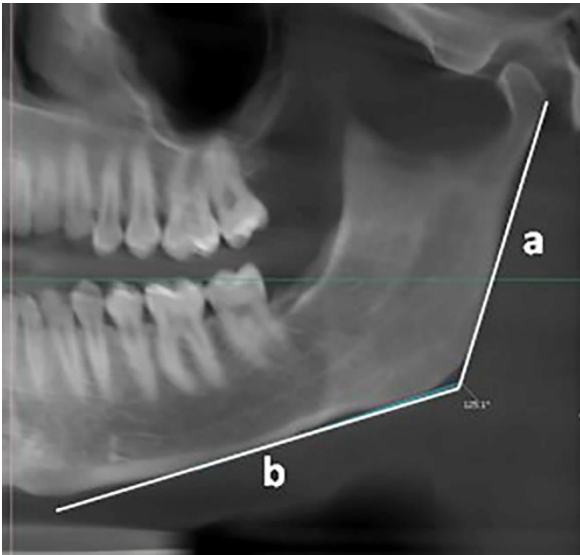


Figure 1: A sample of gonial angle measurement

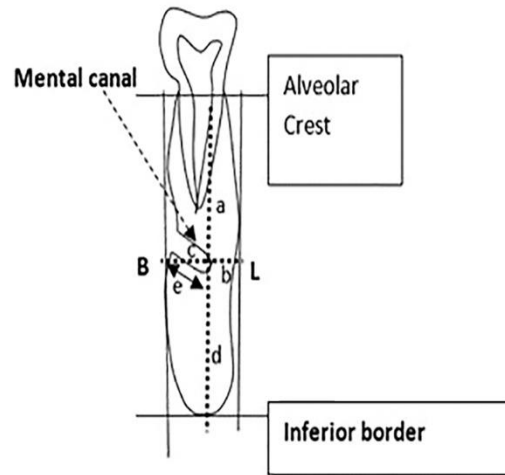


Figure 2: An illustration of measurements in cross-sectional profile of mental foramen: a. Vertical distance, from the lingual end of mental canal to alveolar crest; b. Vertical distance, from the buccal end of mental canal to lingual cortex; c. Vertical distance, from the lingual end of mental canal to the buccal cortex; d. The vertical distance, from the lingual end of mental canal to inferior border of mandible; e. the length of mental canal

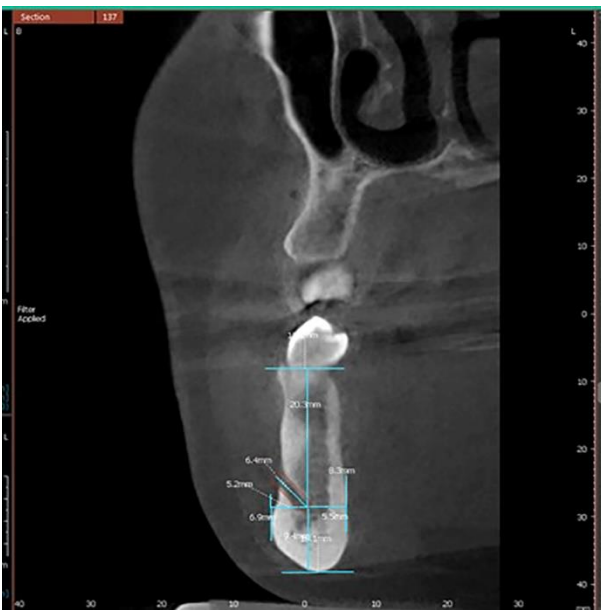


Figure 3: An example of measurements in the cross-sectional profile of mental canal

2) Analysis and measurement of mental foramen (MF) indices: In cross-sectional profiles, the section in which MF had the clearest view, the indices associated with this foramen were examined. The position of mental foramen was determined as follows: Type A = below the apex of first premolar; B = below the apex of second premolar; C = between first and second premolars; D = anteriorly from the first premolar; E = posteriorly from second premolar.

In addition, the frequency of various types of mental foramen in the studied images, were evaluated based on sex and age.

Then, the length of mental canal was measured based on the distance from the lingual end of canal to its opening. Moreover, the vertical distance from the lowest point on the inferior border, buccal cortex, and alveolar crest, plus the distance from buccal end of mental canal to lingual cortex of mandible, were calculated (17) (Figures 2&3).

The statistical analysis was performed using Independent t-test and Chi-square test. The relationship between frequency of position of the MF on the right and left side of mandible, as well as the relationship between sex and position of MF and measurements of mental canal were examined using Chi-square test. Independent t-test was

also used to analyze the relationship between age and position of MF and mental canal measurements, the relationship between MF position and gonial angle and the relationship between mental canal and gonial angle measurements. P-values under 0.05 were considered as statistically significant values.

Results

In this study, 64 CBCT images (a total of 128 gonial angles and mental foramen) were examined for determining the relation between gonial angle, position of mental foramen, and mental canal. The mean age of the subjects was 29.13 ± 8.36 (minimum age 18 years and maximum 49), with a median age of 27 years old.

Based on Table I, the most and least frequent types of MF position on the right belonged to type C and E, respectively. Regarding the left side, the highest occurrence was found as type C and the least as D. There was no significant relationship between frequency of position of MF on right and left side of mandible ($P=0.217$).

According to Table I, there was no relation between sex, age, and position of MF, respectively. (Sex(R/L): $P=0.458$ / $P=0.687$, Age(R/L): $P=0.190$ / $P=0.239$). (Table I)

Table I: Distribution of various types of MF positions

Variables		Type of mental foramen (number)					
		A*	B	C	D	E	
Side	R	3	16	39	4	2	
	L	3	13	44	1	3	
Sex	Female	R	1	7	21	3	2
		L	1	8	23	0	2
	Male	R	2	9	18	1	0
		L	2	5	21	1	1
Age	Under 27yr	R	2	10	19	3	0
		L	2	14	16	1	1
	Above 27yr	R	1	10	16	1	2
		L	1	11	16	0	0
Gonial angle	High	4	17	35	4	1	
	Low	2	12	48	1	4	

* A: below the apex of first premolar; B: below the apex of second premolar; C: between first and second premolars; D: anteriorly from the first premolar; E: posteriorly from second premolar

smaller than the left, and Pearson correlation test showed a significant relation between the two sides ($r=0.8$, $P<0.001$). (Table II)

According to the information in Table II, mean and standard deviation of gonial angle measured on the right side was $121.73^{\circ}\pm 5.38^{\circ}$ and on the left was $124.4^{\circ}\pm 5.00^{\circ}$. The mean gonial angle on the right was about 3 degrees

Table II: Gonial angle measurements in Right and left sides of mandible

Gonial angle	Mean \pm S.D	Max	Min	P-Value	R
Right	121.73 \pm 5.38	138.5	116.5	0.000	0.8
Left	124.4 \pm 5.00	139	114.5		

According to Table I, the highest frequency of MF types in high and low gonial angles was C and the lowest in the mentioned categories was type E and D, respectively. Statistical analysis showed no relation between the position of MF and gonial angle ($P=0.423$).

Among the measurements taken in the high angle group, only the distance from the MF to the lingual plate on the right side followed a normal distribution, and in the low angle group, the length of the mental canal and the distance from the MF to the buccal plate on the left and

the distance from the MF to the inferior border of mandible on the right side followed a normal distribution.

Based on Table III, no significant relationship was found between the measured variables in relation to the mental canal and the gonial angle on both sides ($P>0.05$), but between the measurements on the right and left sides of mandible – in general and not considering gonial angle – a meaningful relation was observed ($P<0.001$).

(Table III)

Table III: Mental canal measurements in association with gonial angle

Measurements (mm)	High angle			Low angle			P-value
	Mean ± SD	Min	Max	Mean ± SD	Min	Max	
Right							
Mental canal length	6.03±0.72	4.70	7.30	6.36±1.00	4.30	8.90	0.143
lin end of MF to inf border ^a	10.40±1.23	8.30	13.30	9.96±1.86	6.80	15.10	0.279
lin end of MF to alv. crest ^b	19.13±2.25	14.90	23.60	18.42±2.02	14.20	22.60	0.188
lin end of MF to BP ^c	3.99±0.52	2.80	5.50	4.20±0.84	3.40	7.30	0.264
Buc end of MF to LP ^d	5.51±1.00	2.90	7.90	5.65±0.92	4.00	8.60	0.560
Left							
Mental canal length	6.21±0.74	4.00	7.50	6.24±1.00	4.40	9.80	0.209
lin end of MF to inf border	10.40±1.22	7.10	12.30	10.17±1.64	7.50	13.60	0.529
lin end of MF to alv. crest	19.11±2.33	13.60	24.00	18.91±2.66	13.60	25.60	0.362
lin end of MF to BP	4.17±0.66	2.90	5.50	4.27±0.78	2.90	6.30	0.584
Buc end of MF to LP	5.41±0.80	4.00	6.70	5.66±1.06	3.80	8.30	0.309

^a: Distance from the lingual end of mental canal to inferior border of mandible; ^b: Distance from the lingual end of mental canal to alveolar crest; ^c: Distance from the lingual end of mental canal to buccal plate; ^d: Distance from buccal end of mental canal to lingual plate.

No relation was revealed between measurements of mental canal with sex and age, table IV and table V (P>0.05). Table (IV, V)

Table IV: Mental canal measurements in association with sex

Measurements (mm)	Male (N=30)			Female (N=34)			P-value
	Mean ± SD	Min	Max	Mean ± SD	Min	Max	
Right							
Mental canal length	6.52±0.94	4.30	8.90	5.95±0.78	4.70	7.80	0.401
lin end of MF to inf border	10.16±1.81	6.80	15.10	10.15±1.43	7.80	13.40	0.440
lin end of MF to alv. crest	18.97±2.43	14.20	22.60	18.55±1.86	14.90	23.60	0.161
lin end of MF to BP	4.15±0.68	3.40	6.40	4.06±0.76	2.80	7.30	0.652
Buc end of MF to LP	5.67±0.68	4.40	7.10	5.51±1.15	2.90	8.60	0.341
Left							
Mental canal length	6.35±0.97	4.40	9.80	6.12±0.79	4.00	7.50	0.340
lin end of MF to inf border	10.27±1.65	7.10	13.60	10.27±1.29	7.80	12.60	0.281

lin end of MF to alv. crest	19.41±2.83	13.60	25.60	18.65±2.14	13.60	24.00	0.462
lin end of MF to BP	4.31±0.74	3.20	6.30	4.15±0.71	2.90	5.60	0.153
Buc end of MF to LP	5.65±0.87	4.00	7.30	5.45±1.03	3.80	8.30	0.441

Table V: Mental canal measurements in association with age

Measurements (mm)	Under 27yr (N=36)			Above 27yr(N=28)			P-value
	Mean ± SD	Min	Max	Mean ± SD	Min	Max	
	Right						
Mental canal length	6.16±0.91	4.30	8.90	6.27±0.89	4.90	7.90	0.641
lin end of MF to inf border	9.92±1.26	7.80	12.20	10.43±1.91	6.80	15.10	0.210
lin end of MF to alv. crest	18.86±2.53	14.20	23.60	18.61±1.61	15.80	21.90	0.432
lin end of MF to BP	4.06±0.54	2.80	5.50	4.15±0.89	3.30	7.30	0.271
Buc end of MF to LP	5.53±0.96	2.90	7.90	5.65±0.96	4.40	8.60	0.621
	Left						
Mental canal length	6.29±0.92	4.40	9.80	6.15±0.84	4.00	7.40	0.673
lin end of MF to inf border	10.28±1.30	7.50	12.80	10.26±1.65	7.10	13.60	0.481
lin end of MF to alv. crest	18.75±2.82	13.60	25.60	19.29±2.08	15.70	24.00	0.132
lin end of MF to BP	4.13±0.66	2.90	5.80	4.33±0.79	2.90	6.30	0.301
Buc end of MF to LP	5.52±0.88	4.00	8.00	5.57±1.05	3.80	8.30	0.392

Discussion

MF is one of the most important anatomical landmarks of mandible and has attracted a lots of attention from various aspects. Positioning, shape, size, distance from other anatomical landmarks, and adjacent roots have been investigated in many studies (18-21). From a clinical perspective, adequate local anesthesia for dental treatments and safety of surgical procedures in this area is influenced by physicians' knowledge of position of MF. This position may also play a role in the interpretation of anatomical landmarks in forensic medicine (19).

In the present study, the most frequent position of MF was observed on the right and left was type C (between the first and second premolars) which is similar to the study by Haqqanifar and Rokui on panoramic images (6).

In the research by Oliviera et al. (21), as well as Khojastehpour et al. (22), the most common position was related to the one below the second premolar. In their anthropometric study, Satini and Alayan(23) examined position of MF in the skulls of 76 Chinese, 46 European and 33 Indians. Mental foramen, in Chinese specimens, was linearly aligned with the axial plane of second premolar, whereas in the European and Indian specimens it was between the first and second premolar. They concluded that population-based differences occur regarding position of MF. In the present study, however, in both high and low gonial angle groups, position of MF was not meaningfully correlated with the age and sex of the subjects, which is similar to Oliviera's findings (21).

According to the findings of the present study, the mean distance of lingual opening of mental canal to inferior border of mandible on the right and left sides was

10.15±1.61 and 10.27±1.46 mm, respectively. In a 2015 study of 26 hemi-mandibles derived from 19 corpses, Yu and colleagues observed that the distance of mental canal to the inferior border was approximately 10.11±1.17 mm, which is almost similar to the results of the current study (24). The distance of lingual end of mental canal to alveolar crest on the right and left sides were 18.74±2.14 and 19.00±2.50mm, respectively. In Oliviera's study, mental foramen was almost in the middle of the distance between the tip of the alveolar process and the inferior border of mandible (21). This difference may be a result of variations in measurements, sample size, race and anatomy.

No significant relation was observed between gonial angle, measured in CBCT images, with measured values of foramen and mental canal. As the present study is the only published study to investigate the relation between gonial angle, position of foramen, and mental canal, further comparisons with other studies would not be possible.

The distance of the lingual opening of mental canal to the inferior border of mandible, and alveolar crest, was not significantly correlated with gender and age of cases in this study ($P>0.05$). In their study, Ozturk et al. (25), did not find the position of MF to be different in age and race groups, but the distance between superior border to inferior border of mandible was significantly different in men and women.

The mean length of mental canal was 6.21±0.89 on the right and 6.22±0.88 mm on the left. The length of measured canal on the right and left sides of mandible were related. Gender and age had no effect on the length of the canal. Yu and his colleagues (24) measured the length of mental canal from the central point in MF to the anterior loop of the mandibular canal. The mean of this distance was 4.34±1.46 mm, which is different from the present results. In Yu et al. study (24), no relation was found between age and gender with mental canal as well.

In this study, the mean distance of the lingual opening of mental canal to the buccal plate of mandible on the right and left sides of the patients was 4.10±0.72 and 4.22±0.73 mm, respectively. The mean distance of buccal opening of canal to the lingual plate on the right and left sides of the images were calculated to be 5.59±0.95 and 5.54 ± 0.96mm, respectively. No significant relationship was found between sex and age of the subjects and distance of mental canal to lingual and buccal plates of mandible. None of the previous studies have investigated the distance between the lingual opening of mental canal to buccal plate and the distance of buccal opening of mental canal to lingual plate, thus a

comparison of the mentioned parameters with previous studies is not possible.

Conclusion

Based on the findings of the present study, the position of the mental foramen was not related to gonial angle, age, and sex of the patients; and since this is the only study of its kind in this field, further investigations with a larger sample size are needed to further confirm the present findings. Considering the previous studies, it is also difficult to precisely determine the location of MF due to its anatomical variations. Also, due to the impact of the racial diversity observed in studies, the use of CBCT images in future, for accurate metrology and careful radiological examinations, seems a necessity in this field.

Conflict of Interest:

There is no conflict of interest.

Acknowledgment:

None Declared

References

1. Angel JS, Mincer HH, Chaudhry J, Scarbecz M. Cone-beam Computed Tomography for analyzing variations in inferior alveolar canal location in adults in relation to age and sex. *J Forensic Sci.* 2011;56(1):216-219.
2. Jacobs R, Mraiwa N, van Steenberghe D, Sanderink G, Quirynen M. Appearance of the mandibular incisive canal on panoramic radiographs. *Surg Radiol Anat.* 2004;26(4):329-333.
3. Naitoh M, Hiraiwa Y, Aimiya H, Gotoh K, Arijji E. Accessory mental foramen assessment using cone-beam computed tomography. *Oral Surg Oral Med Oral Pathol Oral Radiol.* 2009;107(2):289-294.
4. Greenstein G, Tarnow D. The mental foramen and nerve: clinical and anatomical factors related to dental implant placement: a literature review. *J Periodontol.* 2006;77(12):1933-1943.
5. Hasan T, Fauzi M, Hasan D. Bilateral absence of mental foramen—a rare variation. *Int J Anat Variat.* 2010;3(2010):167-169.
6. Haghanifar S, Rokouei M. Radiographic evaluation of the mental foramen in a selected

- Iranian population. *Indian J Dent Res.* 2009;20(2):150-152.
7. Amorim MM., Borini CB., Lopes SLP., Haiter Neto F., Caria PHF. Morphological description of mandibular canal in panoramic radiographs of Brazilian subjects: Association between anatomic characteristics and clinical procedures. *Int.J.Morphol.* 2009;4(2):47-51.
 8. da Silva Ramos LMP, Capelozza ALÁ, Rubira-Bullen IRF. Absence and hypoplasia of the mental foramen detected in CBCT images: a case report. *Surg Radiol Anat.* 2011;33(8):731-734.
 9. Radhakrishnan PD, Varma NKS; Dilemma of gonial angle measurement : panoramic radiograph or lateral cephalogram. *Imaging Sci Dent .* 2017;47(2):93-97
 10. Ohm E, Sliness J. Size of the mandibular jaw angle related to age, tooth retention and gender. *J Oral Rehabil.* 1999; 26(11): 883–891.
 11. Bjork A. Variations in the growth pattern of the human mandible: longitudinal radiographic study by the implant method. *J Dent Res.* 1963; 42(1): 400-411.
 12. Casey DM, Emrich LJ. Changes in the mandibular angle in the edentulous state. *J Prosthet Dent.* 1988;59(3):373-380.
 13. Kaffe I, Ardekian L, Gelerenter I, Taicher S. Location of the mandibular foramen in panoramic radiographs. *Oral Surg Oral Med Oral Pathol Oral Radiol.* 1994;78(5):662-669.
 14. Nicholson ML. A study of the position of the mandibular foramen in the adult human mandible. *Anat Rec.* 1985;212(1):110-112.
 15. Worthington P: Injury to the inferior alveolar nerve during implant placement: A formula for protection of the patient and clinician. *Int J Oral Maxillofac Implants.* 2004; 19(5): 731–734
 16. Anbiaee N, Eslami F, Bagherpour A. Relationship of the Gonial Angle and Inferior Alveolar Canal Course Using Cone Beam Computed Tomography. *J Dent (Tehran).* 2015; 12(10):756-763.
 17. Singh R, Srivastav AK. Study of position, shape, size and incidence of mental foramen and accessory mental foramen in Indian adult human skulls. *Int J Morphol.* 2010;28(4):1141-1146.
 18. Sisman Y, Sahman H, Sekerci A, Tokmak T, Aksu Y, Mavili E. Detection and characterization of the mandibular accessory buccal foramen using CT. *Dentomaxillofac Radiol.* 2012;41(7):558-563.
 19. Parnia F, Moslehifard E, Hafezeqoran A, Mahboub F, Mojaver-Kahnamoui H. Characteristics of anatomical landmarks in the mandibular interforaminal region: a cone-beam computed tomography study. *Med Oral Patol Oral Cir Bucal.* 2012;17(3):e420-e425.
 20. Leite GMF, Lana JP, de Carvalho Machado V, Manzi FR, Souza PEA, Horta MCR. Anatomic variations and lesions of the mandibular canal detected by cone beam computed tomography. *Surg Radiol Anat.* 2014;36(8):795-804.
 21. M. R. de Oliveira J. Morphometrical analysis of the human mandibular canal: a CT investigation. *Surg Radiol Anat .* 2011;33(4):345–352.
 22. Khojastepour L, Mirbeigi S, Mirhadi S, Safaee A. Location of mental foramen in a selected Iranian population: a CBCT assessment. *Iran Endod J.* 2015;10(2):117-121.
 23. Santini A, Alayan I. A comparative anthropometric study of the position of the mental foramen in three populations. *Br Dent J.* 2012;212(4).
 24. Yu SK, Kim S, Kang SG, Kim JH, Lim KO, Hwang SI et al. Morphological assessment of the anterior loop of the mandibular canal in Koreans. *Anat Cell Biol J.* 2015;48(1):75-80.
 25. Ozturk A, Potluri A, Vieira AR: Position and course of the mandibular canal in skulls. *J Oral Surg Oral Med Oral Pathol Oral Radiol.* 2012; 113(4): 453–458.

Corresponding Author

Zahra Yousefi

Dental sciences Research Center, Department of Dentomaxillofacial Radiology, School of Dentistry, Guilan University of Medical Sciences, Rasht, Iran

Tell: 98 (912) 0968522

Email: zahrayousefi71@yahoo.com