

Estimation of Remnant Dentin Thickness under Proximal Caries Using Digital Bitewing Radiography: An *In-Vitro* Study

Masoomeh Afsa¹, Asma Zangizade², Ghader Zargaran³

¹ Department of Maxillofacial Radiology, Faculty of Dentistry, Persian Gulf Oral and Dental Disease Research Center, Hormozgan University of Medical Sciences, Bandar Abbas, Iran

² Dentist, Persian Gulf Oral and Dental Disease Research Center, Hormozgan University of Medical Sciences, Bandar Abbas, Iran

³ Department of Restorative Dentistry, Faculty of Dentistry, Persian Gulf Oral and Dental Disease Research Center, Hormozgan University of Medical Sciences, Bandar Abbas, Iran

Received 2 August 2015 and Accepted 19 November 2015

Abstract

Objectives: In restorative dentistry, it is essential to estimate the amount of remnant tooth structure after caries removal to make the best treatment plan. The present study was aimed to determine whether there is a correlation between the real thickness of remnant dentin under carious lesion and the radiographical measurement from photostimulable phosphor plates (PSPs). **Methods:** a whole number of 68 unrestored permanent human molar and premolar teeth with 82 proximal carious surfaces were mounted in an artificial arch. Digital bitewing radiographs with PSPs were taken, carious lesions were removed and radiographic imaging was repeated. Teeth were sectioned mesiodistally in two parts and thickness of remnant tooth structure to pulp was measured. Measurements of remnant dentin under caries from radiographic images and teeth structures were compared. **Result:** The mean measurements of remnant dentin on primary radiographs were statistically different from the measurements on teeth structures. The mean thickness of remnant dentin on tooth structure was around 30% less than what measured on radiographic image. **Conclusion:** The real thickness of remnant dentin under caries is about 70% of its thickness measured on digital bitewing radiographs prepared by PSPs as image receptor.

Key words: Caries, Bitewing, Radiography.

Afsa M, Zangizade A, Zargaran GH. Estimation of Remnant Dentin Thickness under Proximal Caries using Digital Bitewing Radiography: an in-vitro study. *J Dent Mater Tech* 2016; 5(1): 49-52.

Introduction

Dental caries is one of the most common problems encountered in clinical dentistry and its incidence is very high in populations. Early and accurate diagnosis of caries lesion is essential for clinicians to obtain an exact knowledge of the depth of caries in order to determine the appropriate type of restoration and treatment planning (1). Dental Diagnosticians use conventional or digital bitewing radiographic images as a valuable supplement to clinical examination of the teeth for detecting carious lesions. Comparing with conventional radiography, digital systems have a number of advantages like reduced exposure dose, reduced working time from image exposure to image display, easier image communication and the ability to enhance the quality using provided software. (2-4) Considering these, today there is a steady increase in the use of these technologies in dentistry (4).

There are two basically different types of digital radiography systems available for dental use: a solid-state sensor with or without a cord (charge-coupled device (CCD) or complementary metal oxide semiconductor (CMOS)) and a photostimulable storage phosphor (PSP) plate. The PSP plate surface is ionized when the plate is exposed to X-ray and a latent image is produced. This latent image is read by a red laser beam in a scanner. The laser light stimulates the electrons, whereby energy is emitted in the form of blue light. This is recorded by a photo-multiplier, which turns light into an electronic signal that is digitized (5).

Several studies have shown that radiography only can estimate the depth of carious lesion and the real measurement cannot be achieved. It is expected that

radiographic caries depth is smaller than real measurement acquired from histological examination. The reason for this fact is that in progressive aspect of caries which is toward dental pulp, loss of mineral content is not enough to make a radiolucent shadow visible on radiographic image (4).

For making the best treatment plan in tooth restoration procedures, the clinician employs different radiographic examinations to estimate the amount of intact tooth structure after caries removal. In this regard, present study was aimed to compare the measurements and calculate the ratio of radiographically non-carious dentin between pulp and the deepest point of proximal caries lesions obtained from digital bitewing radiography and real thickness of remnant sound dentine after caries removal. Photostimulable phosphor plates (PSPs) were used as image receptor in radiographic examination.

Materials and Methods

A sample of 68 unrestored extracted human permanent premolar and molar teeth was used in this study. Visually inspected, selected teeth had carious lesions in at least one proximal surface totally 82 surfaces included. (Significance Level 5% and Power 80%).

The teeth were divided into 16 groups including one canine, two premolars and three molars, and mounted in 8 prefabricated upper and lower arches (Dentiform) with proximal surfaces in contact to simulate clinical conditions. One non-test canine tooth was placed at the beginning of the row to create proximal contact for the first test tooth. Dentiforms were mounted in simple articulators to simulate upper and lower jaw relation. A layer of 16mm red wax was used in buccal and lingual aspects of teeth to provide equivalent soft tissue attenuation for x-ray (6).

Bitewing radiographs were acquired using new phosphorplates of an intraoral digital system (Express: Instrumentarium, Helsinki, Finland) and Intra-X (Planmeca, Finland) X-ray machine. Optimal exposure parameters of 70Kvp, 8mA and 0.4sec were selected based on a pilot study. XCP film holders and position indicating devices and positioning jigs were used to provide a distance of 40cm between image receptor and X-ray source and maximize the repeatability of x-ray tube and PSP positions in different radiographic steps. Immediately after exposure, phosphorplates were scanned in Express scanner and saved in DICOM format.

Then, carious lesions were removed using low speed air handpiece and round carbide burs no. 014 & 016 to expose sound dentin. Teeth were mounted in previous order and radiographic procedure was repeated.

Two practitioners, a maxillofacial radiologist and a restorative dentist observed images in a quiet room with dimmed lighting. Digital images were displayed on a 17-inch monitor in a random order using Romexis software 2.4.2. (PlanmecaOy, Finland). Observers were allowed to use enhancement tools of the software. The lowest distance from depth of carious lesion (on primary radiographs) or prepared cavity (on secondary radiographs) to pulp chamber was measured and recorded as D1 and D2, respectively (Fig.1). The interval between first and second observation was two weeks .

Finally, teeth were sectioned mesiodistally into two parts using a diamond disk and were examined under a 10× magnification stereo microscope to measure the thickness of remnant dentin (D3). (Fig.2)

Average measurements made by two observers were analyzed as final data using SPSS 21.0 and ANOVA with repeated measures test.

Fig.1: The thickness of dentin measured on primary (A) and secondary (B) radiographs

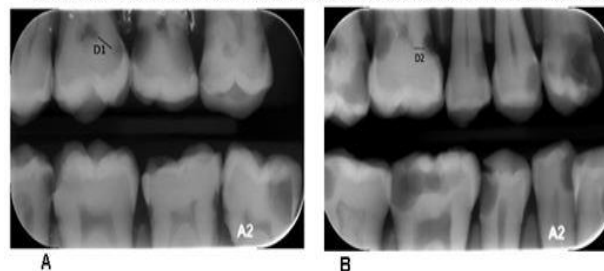
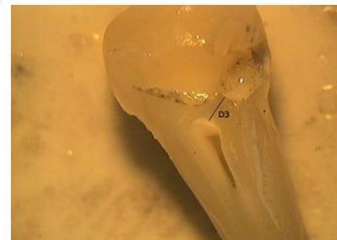

Fig.2: Real thickness of remnant dentin measured on tooth structure



Results

A whole number of 68 teeth and 82 mesial or distal surfaces with carious lesion were studied in this research. Intra Class Correlation (ICC) between two observers for radiographic measurements before caries removal and after caries removal was 92.3% and 91.9% respectively.

The mean values of D1, D2 and D3 were $1.09 \pm .72$, $.75 \pm .71$ and $.78 \pm .75$ mm, respectively (Table 1). Statistically, differences between the measurements of D1 & D2 and also between D1 & D3 were significant ($P < 0.001$ & $P = 0.004$ respectively). But no difference was observed between D2 & D3 ($P = 0.74$). (Table 2)

The ratios of means obtained from D1, D2 and D3 measurements were also calculated. (Table 3).

Table 1. The means of measurements

Measured Distance	Mean (mm)	± SD
D1*	1.09	0.72
D2**	0.75	0.75
D3***	0.78	0.71

*Radiographic measurement of remnant dentin before caries removal.

**Radiographic measurement of remnant dentin after caries removal.

***Real measurement of remnant dentin after caries removal

Table 2. P-value of comparison between groups.

Compared Groups	P value *
D1 & D2	>0.001
D1 & D3	0.004
D2 & D3	0.74

*P value calculated by ANOVA with repeated measures
P < .05 was considered as significant difference

Table 3. Calculated ratio between measurements

Ratio of measurements	Coefficient of accuracy
D2/ D1	0.68
D3/ D1	0.71

Discussion

This study was designed to compare in-vitro the real thickness of remnant sound dentin under proximal tooth caries and its measurement from digital bitewing radiography using photostimulable phosphor plates. Most of the related published studies, have evaluated the accuracy of caries detection of different image receptors. But little have studied the linear measurements of caries depth or remnant dentin.

Beside the benefits of radiographic examination in detecting caries lesions, it is important to note that radiographic examination, using digital system or film based imaging, presents considerable limitations. For

example, one cannot determine if the lesion is active or not, or the presence or absence of cavities.(7) Even if the radiographic exposure geometry is correct, the resulting radiograph tends to underestimate the extension of the lesion compared with the histological examination. (2) In this study, histological examination was not included for determining the unaffected dentin. Instead, the thickness of remnant sound dentin after caries removal was directly measured on tooth structure as gold standard. The reason was that in practice and during dental restorative procedures, the clinician relies on inspection and tactile sense for detecting the sound dentin as a limit for caries removal and cavity preparation in vital pulp situation.

XCP Film holders were used to standardize the radiographic images and to avoid misleading geometric changes in the subsequent images of an individual case .

It is better for radiographic images to be quite dark with good contrast to provide an optimal basis for caries detection. (8) So, observers were allowed to use magnification tool and enhancement filters of the used software to manipulate contrast, density and histogram.

Vivek et al. in their study compared PSP radiographic images with direct measurements using stereomicroscope as the gold standard in detecting proximal caries and found that the diagnostic accuracy of PSP were comparable with that of stereomicroscope (9).

Results of this study show that the thickness of remnant dentin directly measured on tooth structure is 71% of which measured on primary radiographic images. This ratio based on the studies of Ezedini(10) and Khosravi(6) is 57% and 41%, respectively. In these two studies, radiographic high speed films had been employed as image receptor. Whereas digital imaging using PSPs is the method of imaging in our study. We found that the measurements from primary and secondary radiographs and also primary radiographs and tooth structure are significantly different. On the other hand, there is not a significant difference between the measurements of secondary radiographs and tooth structure. The purpose of secondary imaging in this study was to evaluate the effect of radiographic magnification on linear measurements obtained from bitewing images. As it can be seen in Table-1, the mean measurement of remnant dentin from tooth structure is slightly higher than what measured on secondary radiographs (0.78 versus 0.75mm), which is not expected. This may be due to the superimposition of buccal or lingual extension of prepared cavity on proximal portion of the cavity.

Conclusion

In conclusion, if digital bitewing radiography with PSPs as image receptor is used, the real thickness of

remnant dentin under caries is around 30% less than what measured on radiography. Of course, clinical signs and symptoms of patient should also be considered as an important factor to make the best treatment strategy.

References

1. Senel B, Şulu KK, Ucok O, Ksel SY, Ozen T, Avsever H. Diagnostic accuracy of different imaging modalities in detection of proximal caries. *Dentomaxillofacial Radiology*. 2010; 39:501-11.
2. Pontual A, Melo Dd, Almeida Sd, scolo F, Neto FH. Comparison of digital systems and conventional dental film for the detection of approximal enamel caries *Dentomaxillofacial Radiology*. 2010; 39:431-6.
3. Thomson EM, Johnson ON. *Essentials of Dental Radiography for Dental Assistants and Hygienists*. 9th ed2012.
4. White SC, Pharoah MJ. *ORAL RADIOLOGY Principles and Interpretation*. 7 ed2014.
5. Melo DPD, Cruz AD, Melo SIS, Farias JFD, Haiter-neto F, alMeiD SMD. Effect of Different Tube Potential Settings on Caries Detection using PSP Plate and Conventional Film. *ournal of Clinical and Diagnostic Research*. 2015; 9(4):58-61.
6. Khosravi K, Arbabzadeh F. The Comparison of Dentine Thickness under Proximal Caries between Bitewing Radiographs and Tooth Structure. *jdm*. 2001; 14(1):16-22.
7. TORRES MGG, SANTOS AdS, NEVES FS, ARRIAGA ML, CAMPOS PSF, CRUSOÉ-REBELLO I. Assessment of enamel-dentin caries lesions detection using bitewing PSP digital images *J Appl Oral Sci*. 2011; 19(5):462-8.
8. Ulusu T, Bodur H, Odabas M. In vitro comparison of digital and conventional bitewing radiographs for the detection of approximal caries in primary teeth exposed and viewed by a new wireless handheld unit. *Dentomaxillofacial Radiology*. 2010; 39:91-4.
9. Vivek V, Thomas S, Nair BJ, Vineet AD, Thomas J, Ranimol P, et al. Comparison of diagnostic ability of storage phosphorplate in detecting proximal caries with direct measurement by stereomicroscope: a pilot study. *Clinics and Practice*. 2015; 5(763):84-7.
10. Ardekani FE, Davari A, Fatehi M. A comparative study on the dentin thickness under proximal carious in bitewing radiographs and tooth structure. *JIDA*. 2004; 16(3):21-30.

Corresponding Author:

Masoomeh Afsa
Department of Maxillofacial Radiology, Faculty of Dentistry,
Hormozgan University of Medical Sciences,
Bandar Abbas, Iran.
Tel/Fax: +98 - 9173671703
Email: Masoomeh.afsa@hums.ac.ir