

Cusp deflection, infraction and fracture in endodontically treated teeth filled with three temporary filling materials (in vitro)

Ali Eskandarizadeh¹, Molouk Torabi Parizi², Masoud Parirokh³, Ali Taheri⁴

¹Associate professor, Department of Restorative Dentistry, Faculty of Dentistry, Kerman University of Medical Sciences, Kerman, Iran

²Associate professor, Department of Oral Pathology, Faculty of Dentistry, Kerman University of Medical Sciences, Kerman, Iran

³Professors, Department of Endodontics, Faculty of Dentistry, Kerman University of Medical Sciences, Kerman, Iran

⁴Assistant professor, Department of Oral Pathology, Faculty of Dentistry, Kerman University of Medical Sciences, Kerman, Iran

Received 30 May 2015 and accepted 1 September 2015

Abstract

Aim: the aim of this study was to compare cusp deflection, infraction and fracture in teeth filled with three temporary filling materials. **Materials & method:** Forty five extracted human premolar teeth were chosen. After root canal therapy and mesio-occluso-distal cavity preparation, samples were randomly divided into three groups, each contained 15 teeth and filled with three temporary filling materials: Cavisol (Golchai-Iran), Coltisol F (Coltene, Swiss) and Coltene (Ariadent, Iran). Teeth were kept in normal saline at room temperature and every day the intercuspal distance was measured under stereomicroscope for 20 days. Infractions as well as fractures were also noted. Data were analyzed in SPSS 17 using Repeated measurement ANOVA test to evaluate the intercuspal distance and expansion of each sample every day. **Results:** Intercuspal distance increased in all three groups but was significantly more in Coltisol F group. On the days 10 and 16 two teeth filled with Coltisol F had cusp fracture. **Conclusion:** Temporary filling materials have hygroscopic expansion and cause cusp deflection which may lead to cusp fracture, so it is recommended to use them in short period of time.

Key words: temporary filling material, tooth fracture, infraction, cusp deflection.

taheri A, eskandarizade A, torabi parizi M. parirokh M. Cusp deflection, infraction and fracture in endodontically treated teeth filled with three temporary filling material (in vitro). J Dent Mater Tech 2015; 4(4):173-175.

Introduction

Success in root canal therapy depends on complete bacterial debridement, pulp tissue elimination and fine cleaning-shaping of root canal. In some cases the endodontic therapy procedure is not completed in one visit, so a temporary filling material is necessary (1). Lack of proper temporary filling is the second pain remaining factor after treatment (2). Temporary filling material must provide adequate canal seal against bacterial, organic material and oral fluids, preserve tooth remaining structure, have acceptable aesthetic and easy handling (3). Among temporary filling materials, reinforced zinc oxide eugenol and calcium sulfate based materials are more common. Coltisol, Cavit and Kalzinol are common temporary filling brands (4). In 2005 Laustsen et al. claimed that Coltisol F causes cusp deflection, infraction and fracture, if used as a temporary filling material in endodontically treated teeth (5). Lubbers- Coltene chief- disapproved Laustsen results about Coltisol F because of inappropriate method in their study (6). The aim of this study was the evaluation of cusp deflection, infraction and fracture in endodontically treated teeth that were filled with three filling material: Cavisol (golchai, iran), Coltisol F (coltene, swiss) and Coltene (aria dent, iran).

Materials and Methods

Forty five human premolars (thirty maxillary and fifteen mandibular second premolars) extracted for orthodontic treatment with the same size were chosen. Teeth were evaluated under stereomicroscope to be free

of caries and cracks. Access cavity prepared for root canal therapy. Canal shaping was done in passive step back method with K files (Mani, Tochigi, Japan). The master apical file was number 30 and working length was one millimeter to the apex. Master cone was number 30 gutta-percha (Aria dent, Tehran, Iran) and lateral condensation method used for canal obturation. Gutta-percha were cut from orifice. Then MOD cavity prepared in teeth with 4 millimeter Bucco-lingual width, 6 millimeter depth and 1 millimeter above CEJ line and tried to keep pulpal and gingival floor at the same level.

Then teeth divided into three groups of fifteen teeth (ten maxillary and five mandibular premolars). One group filled with Coltoso F, the other with Coltene and last group with Cavisol.

Reference points marked on buccal and lingual cusp tips by needle bars. Samples were kept in normal saline solution at room temperature except for measurement procedure. Thermocycling was done for 700 cycles.

Teeth were observed under stereomicroscope (Zeiss, Jena, Germany) with 20X magnification lens. Two plates and putty used to fix the distance between cusp tips and microscope lens the same for all samples. The photo of each tooth saved in PC and then observed in Photoshop software. The measurement procedure was done every day by two observers for 20 days. Every day, they measured intercusp distance and if their findings were different from the, the mean number was noted as the right distance. At the end of the 20th day, teeth were transferred to methylene blue 1% for 48 hours, washed then thoroughly and existence of cracks was determined for each tooth which now colored in blue.

Repeated-measures ANOVA test used to evaluate the percent of expansion for each temporary filling material. . Mann-Whitney U and Chi-square tests used for comparison of expansion between each two groups and existence of cracks in respect.

Results

Mean intercusp distance at the beginning of the study were 5.43 ± 0.787 mm, 5.51 ± 0.799 mm and 5.844 ± 0.987 mm in teeth filled with Cavisol, Coltoso F and Coltene, respectively. Measurement at the last day of study (20th day) were 5.967 ± 1.344 mm, 6.006 ± 0.754 mm and 5.976 ± 0.985 mm for Cavisol, Coltoso F and Coltene group. The most expansion was for Coltoso F and the least was for Coltene (Table 1). The percent of expansion was 2.55, 3.85 and 8.83 for Coltene, Cavisol and Coltoso F in respect at the end of 20th day. Non parametric Mann-Whitney U test did not prove any significant difference between groups though the Coltoso F had the most expansion. Two teeth filled with Coltoso F had cusp fracture in 10th and 16th days of the study, both were maxillary premolars and fracture

occurred in palatal cusps. At the end of the experiment eight teeth in Cavisol, 12 teeth in Coltoso F and 2 teeth in Coltene group had cracks. Chi square test was significantly different between three groups for number of cracks (Diagram 1).

According to this study Coltoso F had more expansion and inter-cuspal distance changed much more during twenty days which led to cusp fracture in two teeth.

Discussion

Endodontically treated molars and premolars are more prone to cusp fracture than vital teeth (7). Between root canal therapy sessions and after root canal therapy filling with temporary material is necessary (1). Laustsen et al. declared cuspal fracture in teeth filled with Coltoso F (5). Coltoso F contains 40% hemihydrate calcium sulfate which causes 17-20% hygroscopic expansion that leads to cusp fracture. Our results show that all three groups had intercusp expansion but it was more in Coltoso F group. In 2005 Laustsen et al used Coltoso F and ZOE for filling teeth. Seven teeth in Coltoso F group had cusp fracture but there was no fracture in teeth filled with ZOE. The fractures occurred from 8th day of their study. They had two kinds of cavity for each material, one with undercuts that filled with glass ionomer and the other without undercut. More fractures occurred in teeth with undercut. They also found no difference between root canal therapy system and cusp fracture. Lubbers in 2006 replied Laustsen as the chief of Coltene Company (6). He said large cavity preparation and glass ionomer administration in undercuts of the cavity had led to cusp fracture. In the current study, all samples had the same root canal therapy and cavity preparation method, so three groups had the same condition. We tried to eliminate these factors and simulate the study to oral condition, but again cusp fracture occurred only in teeth filled with Coltoso F. In this study, intercusp expansion percent was 3.85% and 2.55 % for Cavisol and Coltene, and 8.83% for Coltoso F which is much more and caused cusp fracture. Unlike two other groups, teeth filled with Coltoso F had continuous expansion during all twenty days of the study. This might be another reason for cusp fracture in Coltoso F.

Table 1. Mean intercuspal distance for each material due 20 days of experiment

	1 st day	10 th day	20 th day
Cavisol	5.430±0.79 mm	5.538±0.78 mm	5.968±1.34 mm
Coltosol F	5.512±0.80 mm	5.735±0.77 mm	6.045±0.76 mm
Coltene	5.844±0.98 mm	5.941±0.99 mm	5.986±0.98 mm
P value	0.385	0.441	0.981

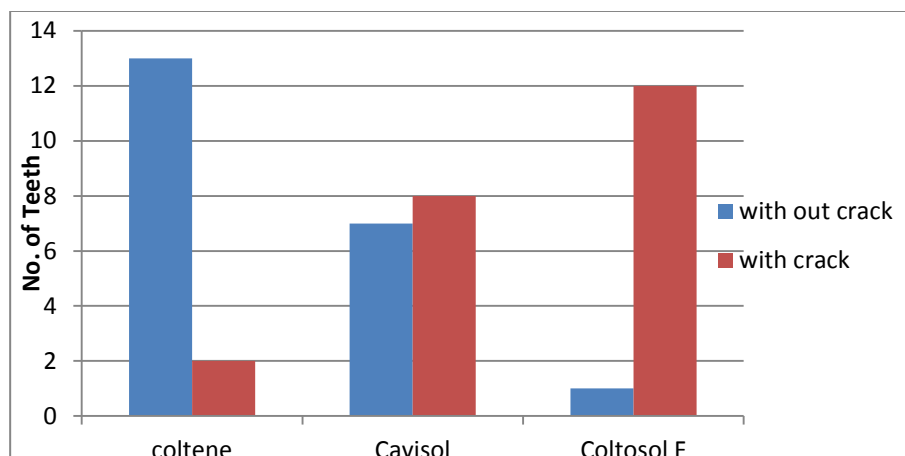


Diagram 1. Number of teeth with or without crack for each group at the end of study

References

1. Sjogren U, Figdor D, Persson S, Sundquist G. Influence of infection at the time of root filling on the outcome of endodontic treatment of teeth with apical periodontitis. *International Endodontic Journal* 1997; 30:297-306.
2. Abbott PV. Factors associated with continuing pain in endodontics. *Australian Dental Journal* 1994; 39:157-61.
3. Wolanek GA, Loushine RJ, Weller RN, Kimbrough WF, Volkmann KR. Bacterial penetration of endodontically treated teeth coronally sealed with a dentin bonding agent. *Journal of Endodontics* 2001; 27:354-7.
4. Widerman FH, Eames EB, Serene TP. The physical and biological properties of cavit. *Journal of the American Dental Association* 1997; 82:378-82.
5. Laustsen MH, Munksgaard EC, Reit C, Bjorndal L. A temporary filling material may cause cusp deflection, infractions and fractures in endodontically treated teeth. *International Endodontics Journal* 2005; 38:653-7.
6. Lubbers D. Letter to the editor. *International Endodontics Journal* 2006; 39:330-1. this article have been used at first.
7. Hannig C, Westphal C, Becker K, Attin T. Fracture resistance of endodontically treated maxillary premolars restored with CAD/CAM ceramic inlays. *J Prosth den* 2005; 94:342-9.

Corresponding Author:

Ali Taheri
 Oral Pathology, Kerman Medical University
 Tel: 09133407651
 E-mail: alitaheri1363@yahoo.com