

Treatment of Labial Mucocele by Intralesional Injection of Dexamethasone: Case Series

Maryam Baharvand¹, Shabnam Sabounchi², Hamed Mortazavi¹

¹ Department of Oral Medicine, Dental School, Shahid Beheshti University of Medical Sciences, Tehran, Iran

² Department of Community Oral Health, Hamadan University of Medical Sciences, Hamadan, Iran

Received 13 March 2014 and Accepted 30 May 2014

Abstract

Salivary mucocele is a common lesion derived from minor salivary glands with various surgical or non-surgical treatment modalities. To evaluate the effect of a highly potent corticosteroid (dexamethasone) in the management of salivary mucocele, we performed intralesional injection of dexamethasone in nine patients with labial mucocele. Complete healing of lesions observed in seven of nine patients, and size reduction in two of them. No local scarring or deformity of the lower lip occurred in any of the patients. One patient reported local discomfort at the site of injection. Intralesional injection of dexamethasone is a potentially curative method in the treatment of mucocele.

Key words: Case report, dexamethasone, mucocele.

Introduction

Salivary mucocele is a common lesion of the minor salivary glands, frequently appears as a single bluish or translucent swelling on the lower lip. Blunt trauma such as lip biting or trauma from adjacent teeth to minor salivary glands may lead to rupture and/or occlusion of the excretory ducts, and terminate to extravasation and accumulation of salivary mucus inside the connective tissue. Two types of mucoceles are known: extravasation type which is mostly seen on the lower lip in the majority of cases; and retention type usually located in the cheek or palate of older patients, completely lined by ductal epithelium and occurs less frequently (1,2).

The diameter of mucoceles ranges from a few millimeters to centimeters. Many patients report periodic discharge of viscous fluid from the lesion. The lower lip is the region mostly affected by mucoceles (1,2).

The differential diagnosis of mucocele includes fibroma, lipoma, hemangioma, traumatic neuroma, schwannoma and salivary gland tumors. Fibroma, lipoma, traumatic neuroma, and schwannoma do not show episodic fluctuations in size over time. Meanwhile, they are different from mucocele in terms of their frequent location, and associated symptoms for example schwannoma is more frequent in the tongue, and traumatic neuroma is accompanied with pain. Hemangioma feels fewer firms to palpation, whereas mucoceles are elastic and fluctuant masses unless they are draining or become chronic with a surrounding fibrous tissue. When located superficially, hemangioma produces a deep blue (if cavernous in origin) to a purple coloration (when originates from capillaries) coloration, while a superficial mucocele appears with a blue hue. Cavernous hemangiomas blanch under pressure due to their emptiability nature (positive diascopy test), but this

Baharvand M, Sabounchi S, Mortazavi H. Treatment of Labial Mucocele by Intralesional Injection of Dexamethasone: Case Series. *J Dent Mater Tech* 2014;3(3):128-33.

is not the case for mucocele. Minor salivary gland tumors are most commonly found in the palate and because of their neoplastic nature and progressive growth they do not have a history of episodic fluctuations in size (3-7).

The overall prognosis is good and various treatments have been proposed such as surgical excision of the lesion with or without removal of the associated gland (1, 2). Because of several unpleasant complications after surgery like lip disfigurement, and damage to adjacent ducts with further development of satellite lesions, many noninvasive methods have been introduced to treat mucocele including cryosurgery, laser micro marsupialization, Gluconate-Mercurius Heel-Potentised Swine Organ Preparations, CO₂ laser ablation, topical and intralesional injection of corticosteroids, and OK- 432 (8-12). Intralesional injections of corticosteroids have been used to treat salivary mucocele with different rates of success (11). Therefore, we decided to evaluate the effect of a highly potent corticosteroid (dexamethasone) on the management of salivary mucocele when injected intralesionally.

Case Report

Nine patients diagnosed clinically by two oral medicine specialists as having salivary mucocele on their lower lips at the Department of Oral Medicine at Shahid Beheshti University of Medical Sciences Dental

School from Oct 2010 to Oct 2012 were entered the study; two of them had recurrent mucoceles. Diagnosis of mucocele was mainly based on its clinical appearance characteristics such as exophytic dome-shaped lesion with smooth surface, bluish color, soft to firm consistency, history of trauma and fluctuation in size (6,13).

Patients with mucoceles on oral rather than labial mucosa, or those not willing to receive injections, or having contraindications for systemic corticosteroids (such as history of tuberculosis, hyperglycemia, hypertension, and osteoporosis) were excluded from the study.

We injected 1ml of 8mg/ml dexamethasone by insulin needles into the base of lesions to prevent any leakage and less discomfort and pain. No local anesthesia was required. Each patient received three consecutive shots with one-week intervals. We examined all patients on days 7, 14, and 21 to evaluate their response and gave them the 2nd and 3rd injections. The size of lesions was measured by means of a dental caliper (Huaxian Gaoping Yuanda Diamond Products Factory, Henan, China) in mm.

All patients were followed later in a mean of 12.5 months (range 6–20 months) after their last injection. Demographic data of patients as well as clinical characteristics of their lesions were summarized in Table 1.

Table 1. Characteristics of mucocele patients underwent intra lesional dexamethasone therapy

Case no #	Sex	Age	Size of lesion (mm)	History of trauma	Previous recurrence	Color	Location	Duration (Days)	No of injections	Result	Follow up (Months)	Complications
1	M*	30	3* 3	TT [†]	Yes	Normal	Lower lip	365	3	R ^{***}	14.5	Local discomfort
2	M	27	15* 15	TLB ^{**}	No	Normal	Lower lip	10	3	Cure	15	None
3	F [†]	17	10* 10	TLB	Yes	Bluish	Lower lip	365	3	Cure	20	None
4	F	25	3* 2	TT	No	Normal	Lower lip	14	3	Cure	17	None
5	F	31	10* 10	TT	No	Bluish	Lower lip	60	3	R	17	None
6	M	25	9* 9	TT	No	Normal	Lower lip	30	3	Cure	8	None
7	F	23	10* 10	TT	No	Bluish	Lower lip	30	3	Cure	5	None
8	M	35	10* 10	TT	No	Normal	Lower lip	60	3	Cure	6	None
9	F	27	10* 10	No	No	Bluish	Lower lip	30	3	Cure	7	None

*M: Male, †F: Female, †TT: Teeth Trauma, **TLB: Trauma due to Lip Biting, ***R: Reduction in size.

Our patients aged from 17 to 35 years with the mean of 26.6. There were four men and five women. Duration of lesions varied from 10 days to one year. In the present study, normal mucosal appearance was seen in five cases whereas four patients had lesions in bluish color. In eight cases out of nine, there was a history of chronic trauma from lip biting or adjacent teeth. The maximum size of all lesions was 1.5 cm. Seven lesions resolved completely following injection (Fig. 1a, b); and two cases showed reduction in size. An excisional

biopsy was taken only from Patient 7 whose lesion was reduced in size after three consecutive injections, but still had interference to eating. Histopathologic study showed normal labial mucosa with no signs of retention phenomena (Fig. 2a, b).

Medical Ethics Committee of Shahid Beheshti University of Medical Sciences approved the study ethically in accordance with Helsinki Declaration. An informed written consent was obtained from all patients before injection.

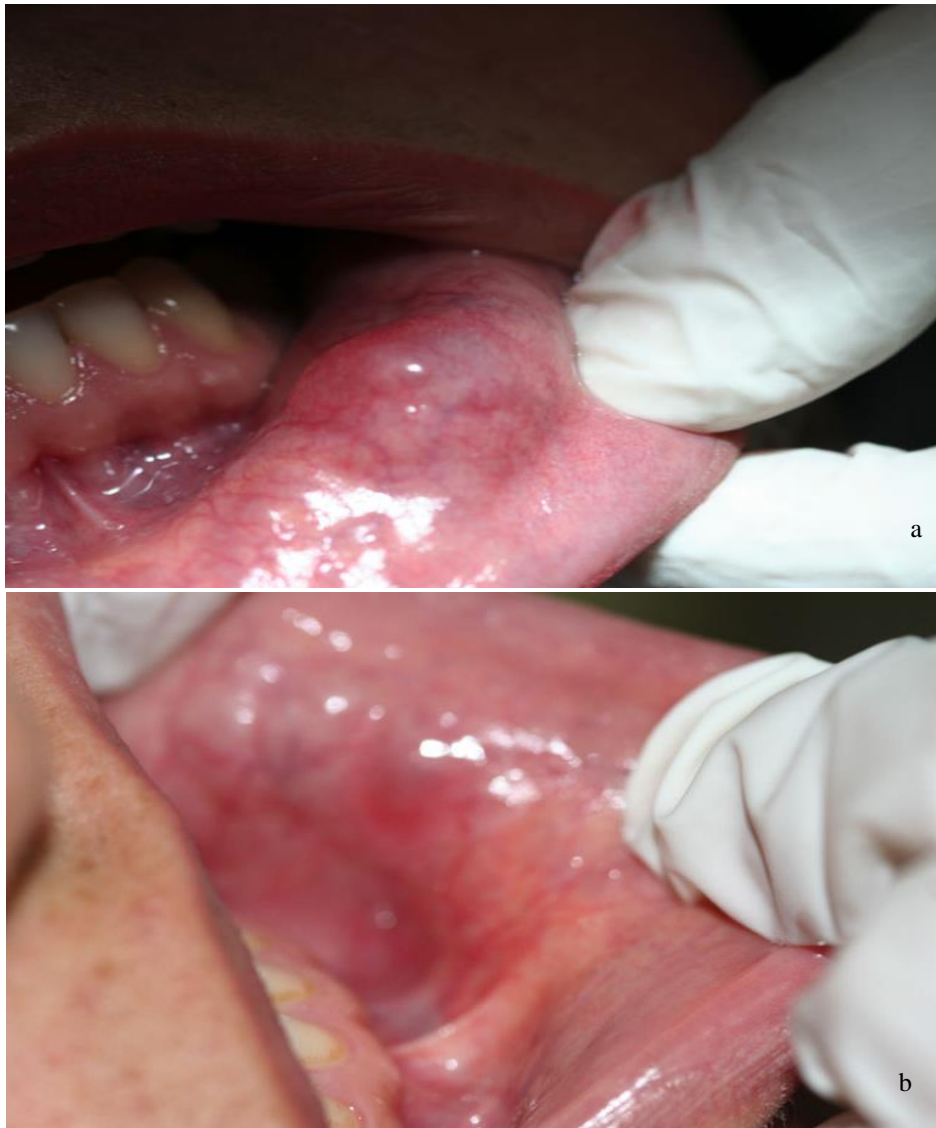

Figure 1. The full size mucocele before (a) and after (b) treatment with intralesional dexamethasone

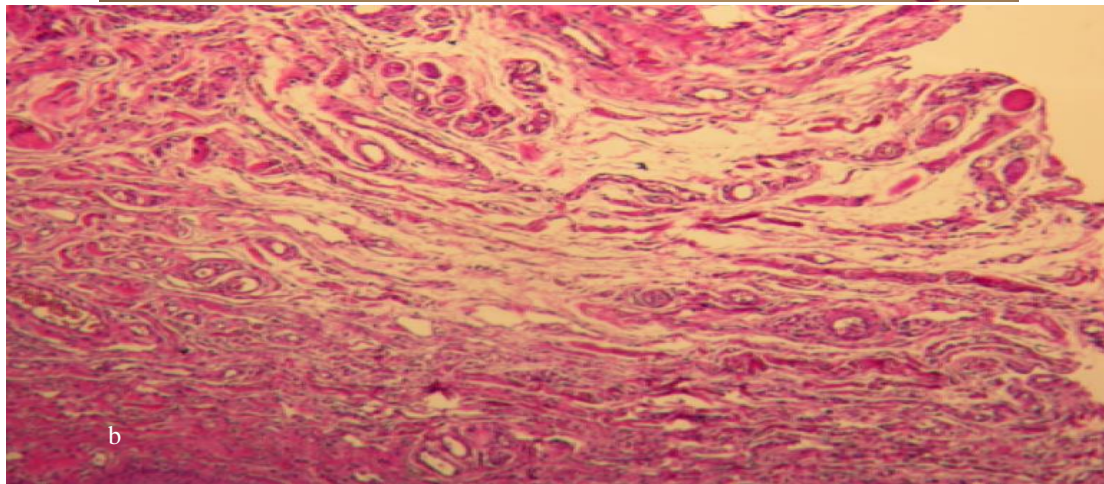
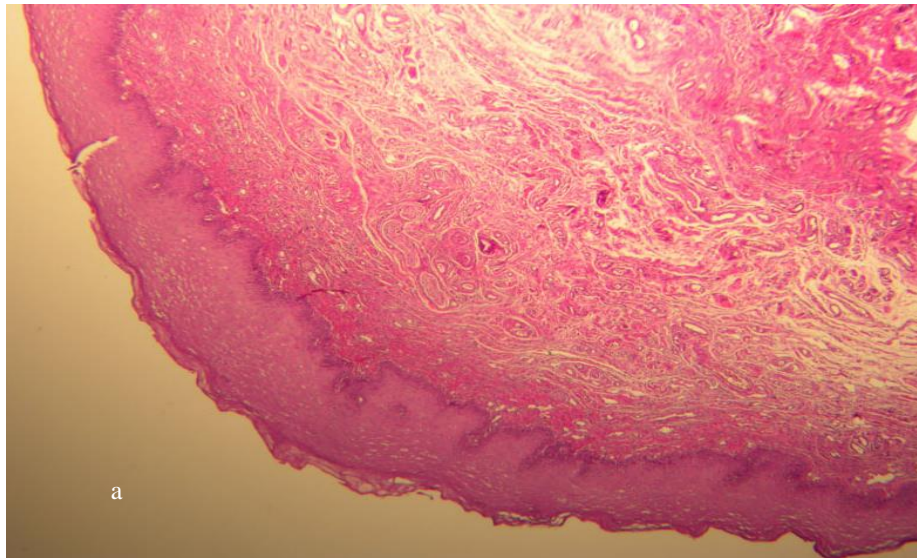


Figure 2a, b. Photomicrographs (H & E staining at *10 and *40 magnifications respectively) of mucocoele remnants after intralesional dexamethasone injection showing normal mucosal architecture without any retention phenomena (Courtesy to Dr. F. Mashadi-Abbas)

Discussion

In order to evaluate the effectiveness and probable complications of intralesional dexamethasone therapy, this initial study was performed on nine patients with salivary labial mucocele. We used a highly potent corticosteroid, dexamethasone, because in previous studies intralesional injection of a moderately potent corticosteroid, triamcinolone, was associated with relapses (11, 14). Injection of a high-potency topical corticosteroid has been described in treatment of painful and recurrent oral mucocele by Luiz et al. (14). It seems that corticosteroids promote the shrinkage of dilated salivary ducts or pools like a sclerosing agent (14).

The main accepted treatment for mucocele is surgical extirpation of the surrounding mucosa and glandular tissue down to the muscle layer. However,

Yamasoba et al. (15) showed a 2.8% recurrence in the lesions which were removed surgically. Except for conventional surgical treatments, there are some conservative methods such as:

Cryosurgery, laser ablation, Gluconate-Mercurius Heel-Potentised Swine Organ, micro-marsupialization, and conventional surgical removal of the lesion (8-10, 12). However, some of these techniques need special and expensive armamentaria, or may be associated with relapses and therefore, require reintervention in the form of conventional surgery to ensure complete resolution of the lesions. Yagüe-Garcia et al. (10) compared scalpel versus CO₂ laser to treat mucocele. He concluded that patients underwent conventional surgery had postoperative complications and recurrence, whereas CO₂ laser ablation was rapid, simple, and effective, but

the equipment is expensive, and adequate protection must be provided for the patient and operator. Ohta et al. (12) performed OK-432 (Picibanil, a lyophilized streptococcal preparation made by penicillin treatment of the Su-strain of A-group Streptococcus) injection therapy and reported that OK-432 was inexpensive and required no special equipment or medication compared with office treatment by the other modalities including CO₂ laser, or Nickel Gluconate-Mercurius Heel-Potentised Swine Organ preparations (a Homotoxicological agent). However OK-432 is not available in all countries (12).

Seven out of our nine patients treated with dexamethasone, cured completely, and two persons showed decrease in size of their lesions. No deformity or infection was observed after intralesional injection of dexamethasone. An excisional biopsy was taken from patient 7 whose lesion was reduced in size but still caused discomfort during eating (Fig. 1a, b). Histopathologic study showed normal labial mucosa with no signs of retention phenomena (Fig. 2a, b). It seems that corticosteroids promote the shrinkage of dilated salivary ducts or pools like a sclerosing agent.

The treatment had minimal pain and no local anesthesia was required. However, local discomfort of lower lip was observed in one patient after injection. The time of procedure was short, so it can be well tolerated by children. In regard to cost effectiveness, dexamethasone injection therapy is economically and esthetically more advantageous than surgery, cryotherapy or laser ablation. It can be available in almost every medical or dental setting for a low price.

After at least six months of follow up of our patients, no recurrence was observed among those cured or had remarkable shrinkage. This is a comprehensive technical report to show that salivary mucocele can be treated or reduced in size by the use of dexamethasone. Since we had no control group, randomized controlled trials to compare it with conventional surgery or placebo injection may be warranted.

Conclusion

Injection of dexamethasone is a simple, repeatable, cost effective and potentially curative method of treatment, and can be used as the first choice or substitute for surgery in the treatment of salivary mucocele.

Acknowledgement

The authors are greatly thankful to the staff members of Oral Medicine Department of Shahid Beheshti University of Medical Sciences Dental School for their close cooperation.

References

1. Re Cecconi D, Achilli A, Tarozzi M, et al. Mucoceles of the oral cavity: A large case series (1994–2008) and a literature review. *Med Oral Patol Oral Cir Bucal* 2010;15:e551-6.
2. Ata-Ali J, Carrillo C, Bonet C, Balaguer J, Peñarrocha M, Peñarrocha M. Oral mucocele: review of the literature. *J Clin Exp Dent* 2010;2:e18-21.
3. Jaafari Ashkavandi Z, Dehghani Nazhvani A, Hamzavi M. Mucocele accompanied by a traumatic neuroma: a case report. *J Dent (Shiraz)* 2013;14:46-8.
4. Valério RA, Queiroz AM, Romualdo PC, Brentegani LG, Paula-Silva FW. Mucocele and fibroma: treatment and clinical features for differential diagnosis. *Braz Dent J* 2013;24:537-41.
5. Gudi SS, Sikkerimath BC, Puranik RS, Kasbe SS. Swelling on lower lip...not always a mucocele. *Ann Maxillofac Surg* 2013;3:98-9.
6. Chi AC, Lambert PR 3rd, Richardson MS, Neville BW. Oral mucoceles: a clinicopathologic review of 1,824 cases, including unusual variants. *J Oral Maxillofac Surg* 2011;69:1086-93.
7. Baurmash HD. Mucoceles and ranulas. *J Oral Maxillofac Surg* 2003;61:369-78.
8. Twetman S, Isaksson S. Cryosurgical treatment of mucocele in children. *Am J Dent* 1990;3:175-6.
9. Garofalo S, Briganti V, Cavallaro S, et al. Nickel Gluconate-Mercurius Heel-Potentised Swine Organ Preparations: a new therapeutical approach for the primary treatment of pediatric ranula and intraoral mucocele. *Int J Pediatr Otorhinolaryngol* 2007;71:247-55.
10. Yagüe-García J, España-Tost AJ, Berini-Aytés L, Gay-Escoda C. Treatment of oral mucocele-scalpel versus CO₂ laser. *Med Oral Patol Oral Cir Bucal* 2009; 149:e469-74.
11. Wilcox JW, History JE. Nonsurgical resolution of mucoceles. *J Oral Surg* 1978;36:478.

12. Ohta N, Fukase S, Suzuki Y, Aoyagi M. Treatment of salivary mucocele of the lower lip by OK-432. *Auris Nasus Larynx* 2011;38:240-3.
13. Khandelwal S, Patil S. Oral mucoceles - review of the literature. *Minerva Stomatol* 2012;61:91-9.
14. Luiz AC, Hiraki KR, Lemos CA Jr, Hirota SK, Migliari DA. Treatment of painful and recurrent oral mucoceles with a high-potency topical corticosteroid: a case report. *J Oral Maxillofac Surg* 2008;66:1737-9.
15. Yamasoba T, Tayama N, Syoji M, Fukuta M. Clinicostatistical study of lower lip mucoceles. *Head Neck* 1990;12:316-20.

Corresponding Author:

Hamed Mortazavi
Department of Oral Medicine
Dental School, Shahid Beheshti University of Medical Sciences
Daneshjoo Blvd, Tabnak St, Chamran Highway, Tehran, Iran
Postal Code: 19839-63113
Tel: 02129902311
Fax: 02122403194
E-mail: hamedmoratazavi2013@gmail.com