

# An Innovative Rigid Tray Technique for Replacement and Reattachment of the Anterior Composite Tooth Pontic

Saied Mostafa Moazzami<sup>1</sup>, Atefeh Atoufi<sup>2</sup>, Sara Sarvari<sup>3</sup>,  
Michael Meharry<sup>4</sup>

<sup>1</sup> Dental Research Center, Department of Operative and Esthetic Dentistry, School of Dentistry, Mashhad University of Medical Sciences, Mashhad, Iran

<sup>2</sup> Department of Operative and Esthetic Dentistry, School of Dentistry, Mashhad University of Medical Sciences, Mashhad, Iran

<sup>3</sup> Private Dentist, Mashhad, Iran

<sup>4</sup> Department of Restorative Dentistry, Center for Dental Research, Loma Linda University School of Dentistry, Loma Linda, CA, USA

*Received 7 April 2014 and Accepted 15 May 2014*

## Abstract

Replacement and reattachment of a newly detached composite tooth pontic is sometimes justified because of shape, color, function and patient satisfaction.

The aim of this case report is to describe a new method using Rigid Tray Technique for exact replacement and reattachment of acceptable detached composite tooth pontic.

**Key words:** Composite tooth pontic, dental trauma, reattachment, replacement.

## Introduction

Dental traumatic injuries, which can lead to a wide range of injuries, are the most common damages among all facial injuries particularly among children and teenagers (1-3). Most dental injuries occur between 2 and 3 years and between 8 and 12 years of old (4). It has been reported that the prevalence of dental trauma involving anterior teeth is 37% (5).

The most commonly affected teeth are maxillary central incisors (80%) (6). This high incidence can be related to the anterior labial position and protrusion caused by eruptive process (7).

In such tragic experiences, immediate intervention is necessary not only because of damage to the dentition, esthetics, function and phonetics (8), but also due to psychological impact it would make on the patients (9).

The advances in modern adhesive dentistry have created the opportunity for the dentists to use the patient's own tooth fragment to restore the fractured tooth. Reattachment is such an ultraconservative technique which provides safe, fast, and esthetically pleasing results (4).

Various therapeutic solutions can be used to replace a single missing tooth. The development of implant-supported restorations led to a more conservative and ideal approach to a single-tooth replacement. However, in some patients this therapeutic option is rejected, because of the lower age, time, higher cost, systemic problems and other contraindications. Other treatment

---

Moazzami SM, Atoufi A, Sarvari S, Meharry M. An Innovative Rigid Tray Technique for Replacement and Reattachment of the Anterior Composite Tooth Pontic. *J Dent Mater Tech* 2014; 3(3):92-8.

approach such as conservative bridge, removable and fixed partial denture is recommended (10).

The conservative bridges are specially indicated for young patients because the teeth usually have large pulp chambers and short clinical crowns. They can be viable alternative to conventional fixed bridges in circumstances where age, expense, and clinical impracticality are among the considerations. Superior esthetics and reversibility are among the advantages of an all porcelain, acrylic and composite tooth pontics. This is a major benefit in young patients, where this pontics can be placed as interim restoration until implants or a more permanent prosthesis can be placed at an older age. The conservative bridges are classified according to the type of pontic: a: Natural tooth pontic b: Porcelain-fused-to-metal pontic or all-metal pontic with metal retainers c: All porcelain pontic, and d: Denture or Composite tooth pontic (11).

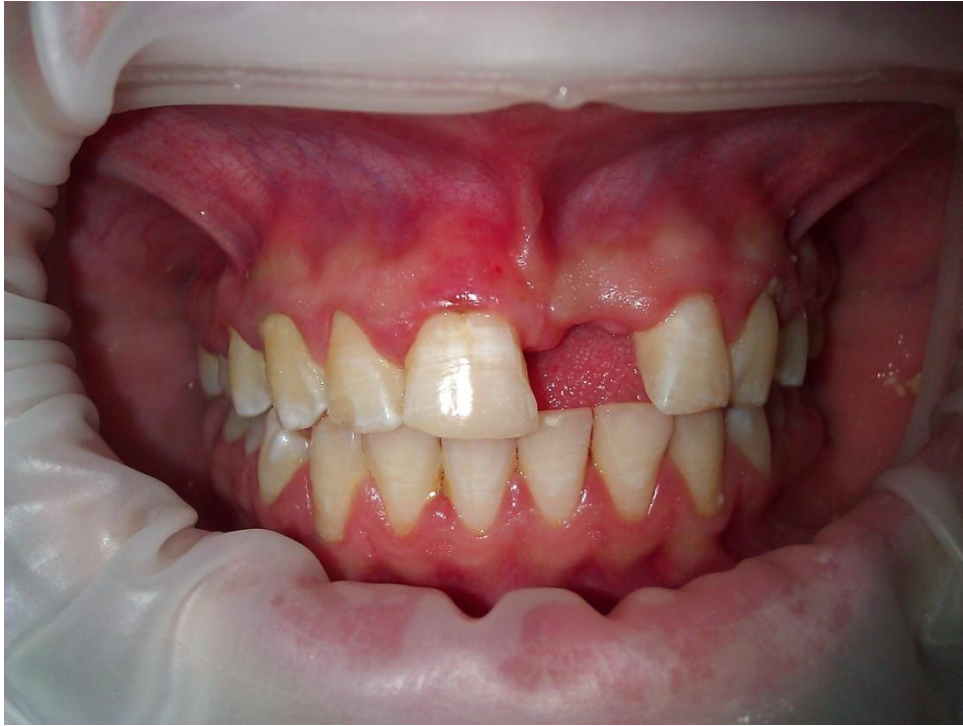In case of repeated dental traumatic injuries, replacement and reattachment of the acceptable fractured porcelain, composite, and natural tooth pontic at the exact or proper place is difficult and sometimes impossible. They have performed by various procedures, such as establishment by hand or by using putty impression material. Anyway, the importance is accuracy of the used technique.

The aim of this report is to describe a new method using Rigid Tray Technique (RTT) for accurate replacement and reattachment of the detached composite tooth pontic.

## **Description of Technique**

A 14-year-old girl was referred to the clinic with a chief complaint of detached left upper central incisor composite tooth pontic. Case history showed a dental trauma happened three month ago which caused the tooth to be lost. It was replaced with an acceptable composite tooth pontic a week ago and it was detached because of occlusal interference and bonding failure after a week. The patient had her own intact composite tooth pontic. The patient's age; adjacent teeth and pontic position; material and equipment; and satisfaction from the previous artistically-made composite tooth pontic as well as the question of time and economy lead us to innovate a new technique for replacing and reattaching the existing pontic. The following procedure has been adopted for the treatment of the case based essentially on making a special rigid tray:

1-Examination: Adjacent teeth, periodontal status, occlusion, esthetics and quality of the pontic were checked (Fig. 1).

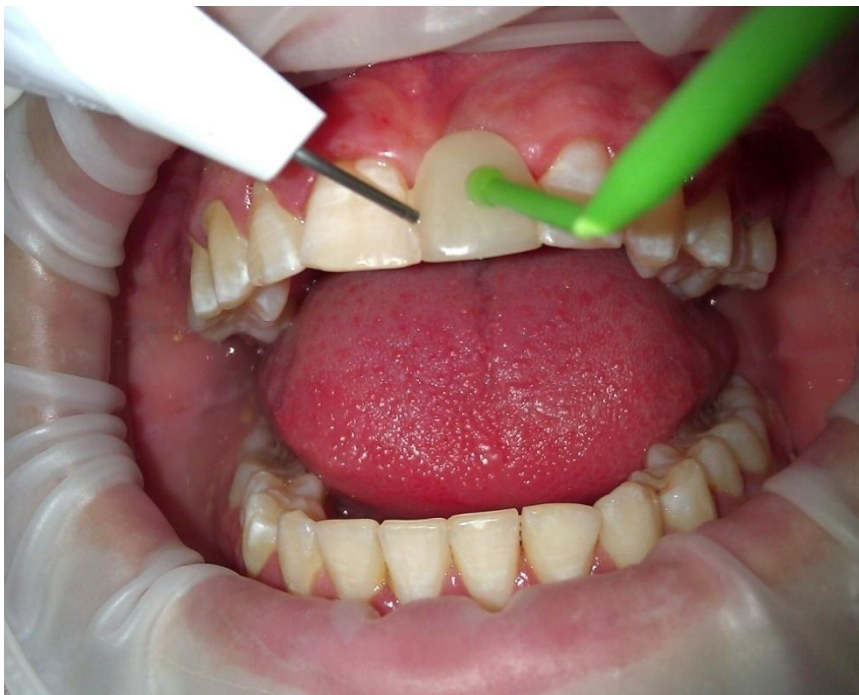

**Figure 1.** Missed/detached composite tooth pontic

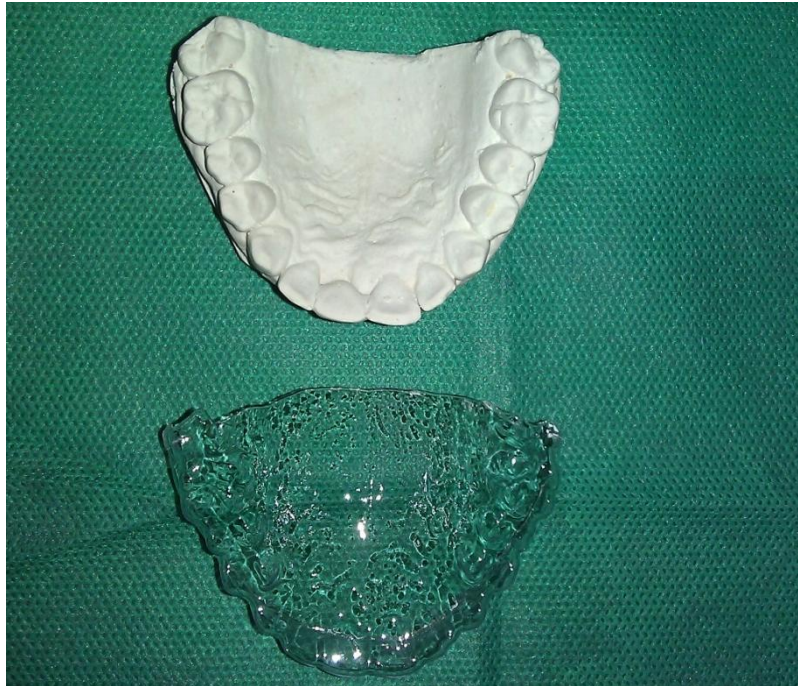2-Temporary stabilization: Considering the occlusion, the pontic was fixed in its proper place using a stick to non-etched enamel of adjacent teeth with flowable composite (Fig. 2).

3-Taking impression: An alginate impression (AROMA FINE DF III, GC CORPORATION, 76-1

HASUNDUMA-CHO, ITABASHI-KU, TOKYO, JAPAN) was taken from the treatment arch while the detached pontic was in its exact place.



**Figure 2.** Temporary stabilizing the pontic with flowable composite



**Figure 3.** Prepared rigid tray

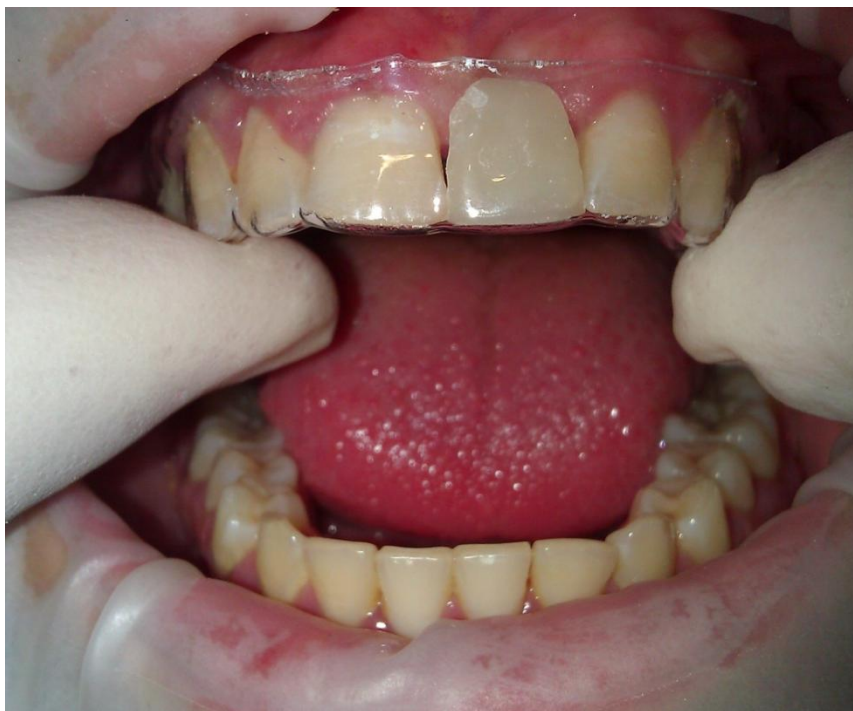4-Making master/working cast: Using dental stone (Moldano, Bayer, Leverkusen, Germany) a master/working cast was made.

5-Making a rigid tray: A thermoplastic 0.9 mm thick rigid tray (Rigid-Tray® Sheets, ULTRADENT PRODUCTS. INC, USA) was fabricated over the master cast using a vacuum press machine (T&S Dental & Plastic Co. USA) (Fig. 3). The tray was trimmed off using a scalpel blade 3-5 mm apical to the gingival margin. A pair of small curved scissors can be used to remove the rough edges if necessary. The fit was checked by matching the tray with the master cast and rechecked in the patient's upper teeth (Fig. 4).

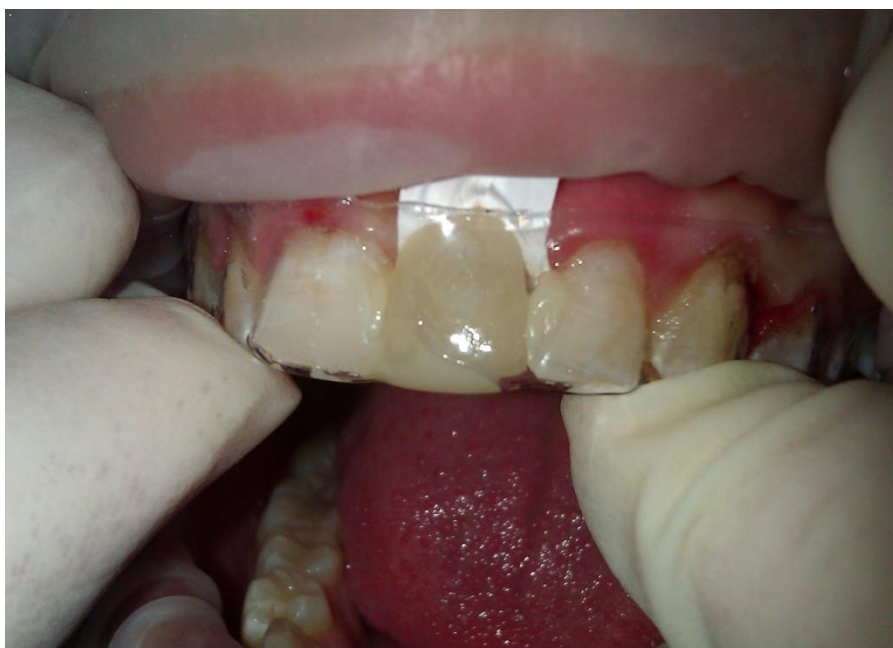6- Surface preparation: The composite remnant of the proximal bonding surfaces of abutment teeth were removed and freshened with a coarse diamond bur with suitable shape. Then their proximal, labial and lingual line angles were slightly beveled. The adjacent surfaces of the pontic were treated in the same manner as well. After isolation, etching (with 37% phosphoric acid),

washing, drying and applying the bonding agent were done on both prepared enamel and pontic surfaces as instructed by the manufacturer's instructions. A Folded Teflon band was placed over the gingiva just beneath the pontic which was to be reattached.

7-Reattachment: The prepared pontic was placed exactly in its place within the rigid splint. A thin layer of flowable composite (Ultradent Products. INC, USA) was brushed on the bonding surfaces of the pontic and adjacent teeth. Thin layers of composites (Ultradent Products. INC, USA) were then placed over the flowable ones. The pontic containing splint was placed in its proper position with great caution (Fig. 5). The composites were cured with the light curing units (Astralis 7, Ivoclar/ Vivadent, Liechtenstein) with their LOP program ( $400\text{mw}/\text{cm}^2$ ) for 40 seconds through the tray from both sides simultaneously.



**Figure 4.** Checking the tray while the detached pontic in its place

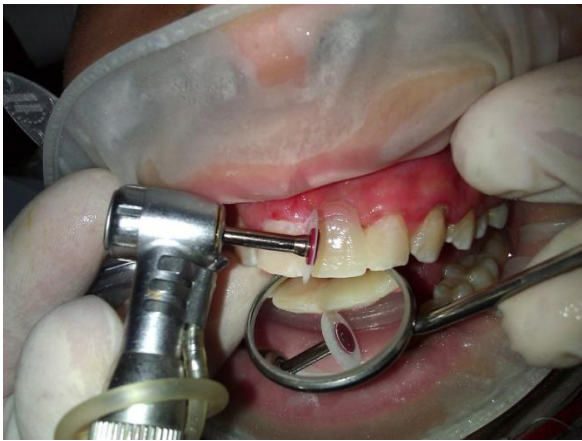

**Figure 5.** Placing the splint containing the prepared pontic in its proper position

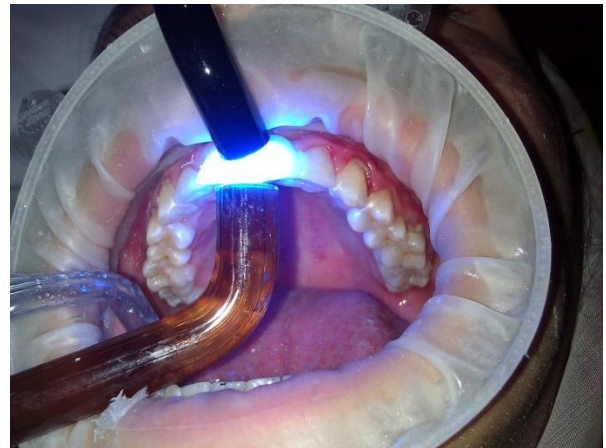
8- Finalizing the restoration and occlusal adjustment: Excess composite was removed to make an appropriate shape with diamond bur using high speed handpiece and cooling water. If necessary, the color and texture can be corrected in this step. In order to follow the golden proportion rule in this case, gingival part of the pontic was formed by gingiva-colored composite. Next the occlusion was carefully adjusted. Then finishing and polishing were done with # 12 scalpel, diamond burs, Softflex polishing disks (3M, ESPE,

USA), polishing cups and points (Fig. 6). The glazing agent (Permaseal, Ultradent Products. INC, USA) was used as manufacturers' instructions. Post curing was done with HIP program ( $750 \text{ mw/cm}^2$ ) for 40 seconds from both buccal and lingual sides with two light cure units simultaneously (Figs. 7 and 8). Scaling, polishing and oral hygiene instruction were done for the patient.

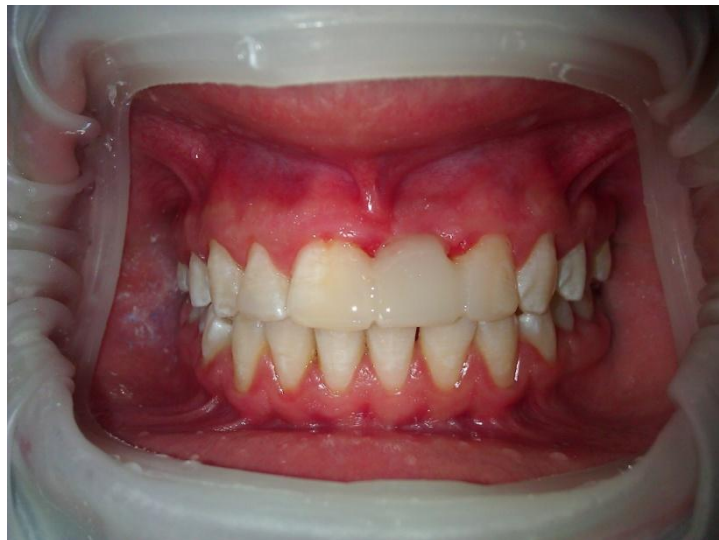9- Removing the rigid tray: After initial setting, the tray was carefully removed. Next the Teflon band was removed



**Figure 6.** Finishing and polishing



**Figure 7.** Post curing both from buccal and lingual simultaneously



**Figure 8.** Final result

**Table 1.** List of materials and device used in this study

Purpose/Step	Materials or Device	Specification
Taking impressions/ 3	Alginate impression material	AROMA FINE DF III, GC CORPORATION 76-1 HASUNDUMA-CHO, ITABASHI-KU TOKYO, JAPAN
Making master casts/ 4	Hard Plaster for models	Moldano, Bayer, Leverkusen, Germany
Making a rigid tray/ 5	Vacuum press unit	T&S Dental & Plastic Co. USA
Making a rigid tray/ 5	Rigid sheet	Rigid-Tray® Sheets, ULTRADENT PRODUCTS. INC., 505 West 10200 South, South Jordan, UTAH 84095, USA

Acid Etching/6	Phosphoric Acid 37%	Ultra-Etch® ULTRADENT PRODUCTS. INC., 505 West 10200 South, South Jordan, UTAH 84095, USA
Adhesive technique/6	Bonding agent	Margin Bond® Coltène/Whaledent AG, Feldwiesenstrasse 20 9450Altstätten, Switzerland
Temporary fixation and bonding/2 and 7	Flowable Composite (A1)	GRADIA Direct Flo, GC CORPORATION, 76-1 HASUNDUMA-CHO, ITABASHI-KU, TOKYO, JAPAN
Bonding/7	Composite resin	Ultradent Products. INC, USA
Glaze/8	Permaseal	Ultradent Products. INC, USA
Light Curing process/2,7 and 8	Light Cure unit	Astralis7, Ivoclar/ Vivadent, Liechtenstein

### Potential Problems

The only potential problem is availability of vacuum former and rigid sheet needed for making the rigid tray.

### Summary of Advantages/Disadvantages

RTT is an easy, practical and efficient single-visit treatment. Since RTT has minimal laboratory procedures, it is also a cost effective and time-saving method.

The disadvantages of RTT are availability of the rigid sheet and vacuum former needed for making a rigid tray. The procedure is somewhat technically complex and takes a bit more chair time.

### Conclusion

The novel RTT may sometimes be the best and only way for replacement and reattachment of a detached tooth pontic. It is an artistic technique for replacement and reattachment of a composite tooth pontic that can be used in restorative dentistry to bring satisfaction to the dentists concerned about their patients' welfare.

### Acknowledgment

This case was done in postgraduate program clinic of Department of Operative and Esthetic Dentistry of Mashhad Dental School, Mashhad Dental Research Center, Mashhad University of Medical Sciences and private dental office of the corresponding author, Mashhad, Iran.

### References

1. Sheikh-Nezami M, Mokhber N, Shamsian K, Saket S. Management of a midroot and complicated crown fracture: a case report. *Oral Surg Oral Med Oral Pathol Oral Radiol Endod* 2009;107:e65-7.
2. Kumari NB, Sujana V, Sunil CH, Reddy PS. Reattachment of complicated tooth fracture: An alternative approach. *Contemp Clin Dent* 2012;3:242-4.
3. Chu FC, Yim TM, Wei SH. Clinical considerations for reattachment of tooth fragments. *Quintessence Int* 2000;31:385-91.
4. Vishwanth B, Faizudin U, Jajadev M. Reattachment of Coronal Tooth Fragment: Regaining back to normal. *Case Rep Dent* 2013;2013:286186.
5. Andreasen JO, Andreasen FM. Text book and color atlas of traumatic injuries to the teeth. Copenhagen: Munksgaard, 1993.
6. Ivancic Jokic N, Bakarcic D, Fugosic V, Majstorovic M, Skrinjaric I. Dental trauma in children and young adults visiting a University Dental Clinic. *Dent Traumatol* 2009;25:84-7.
7. Lo Giudice G, Lipari F, Lizio A. Tooth fragment reattachment technique on apluri traumatized tooth. *J Conserv Dent* 2012;15:80-83.

8. Bagis B, Korkmaz YT, Korkmaz FM, Durkan R, Pampu AA. Complicated subgingivally fractured central and lateral incisors: case report. *J Can Dent Assoc* 2011;77:b145.
9. Patni P, Jain D, Goel G. A holistic approach to management of fractured teeth fragments: a case report. *Oral Surg Oral Med Oral Pathol Oral Radiol Endod* 2010;109:e70-4.
10. Kermanshah H, Motevasselian F. Immediate tooth replacement using fiber-reinforced composite and natural tooth pontic. *Oper Dent* 2010;35:238-45.
11. Roberson TM, Heymann HO, Swift EJ. *Art and Science of Operative Dentistry*. St. Louis: Mosby Inc, 2013.

**Corresponding Author:**

Saied Mostafa Moazzami

Department of Operative and Esthetic Dentistry

Faculty of Dentistry, Vakilabad Blvd, Mashhad, Iran

P. O. Box: 91735-984

Tel: +98 511 8829501

Fax: +98 511 8829500

E-mail: MoazzamiM@mums.ac.ir & smm1342@yahoo.com