

Stability of anterior open bite treated with crib appliance in mixed dentition: A systematic review

Houda Ousli^{1*}, Afaf Houbdine¹, Hajar Benmohimd¹, Fatima Zaoui¹

Abstract

Objective: This study aimed to evaluate the stability of dentoalveolar and skeletal anterior open bite (AOB) treatment outcomes achieved using a crib appliance.

Methods: An electronic search was performed in Scopus, PubMed, Web of Science, ScienceDirect, and the Cochrane Library to identify studies published up to December 2024. The search focused on in vivo studies evaluating the stability of dentoalveolar and skeletal correction of AOB using crib appliances. A total of 451 potentially relevant publications were identified, of which five met the inclusion criteria, comprising one randomized controlled trial and four non-randomized trials. Follow-up periods ranged from 12 months to 5 years.

Results: The included studies suggest that crib appliances, often used in combination with other orthodontic devices, may contribute to the favorable correction and stability of AOB treatment during the mixed dentition phase. The studies reported stability rates up to 95%. The fixed palatal crib appliance demonstrated the highest stability and the lowest relapse rate. However, most studies combined cribs with other orthodontic appliances, follow-up durations were variable, and substantial methodological heterogeneity was present among the included investigations, highlighting the need for further well-designed longitudinal studies to confirm these findings.

Conclusions: Crib appliances appear to be effective in correcting anterior open bite and maintaining treatment stability.

Keywords: Mixed dentition, Open bite, Orthodontic appliances, Relapse, Removable appliance, Stability

Introduction

Anterior open bite (AOB) is defined as the absence of normal vertical overlap between the incisal edges of opposing teeth when the posterior dentition is in occlusion (1, 2). During the mixed dentition phase, the prevalence of AOB can be as high as 17% (3). However, several studies have demonstrated that the prevalence of AOB decreases with increasing age (3, 4). This decline in the prevalence of AOB is generally attributed to normal occlusal development, neurological maturation leading to the spontaneous cessation of deleterious oral habits, regression of adenoid hypertrophy, and the transition to a mature swallowing pattern (2, 5, 6).

Open-bite malocclusion is classified into three categories: dentoalveolar, skeletal, and combined open bite (7, 8). The etiology of AOB is multifactorial, involving a complex interaction of contributing factors such as

persistent oral habits, abnormalities in tongue size or function, mouth breathing, vertical facial growth patterns, congenital conditions, and acquired disorders. Additionally, local factors like dental ankylosis and eruption disturbances may play a role in developing AOB. Among habitual behaviours, thumb sucking, prolonged pacifier use, abnormal lip posture, and dysfunctional tongue movements are the most frequently implicated etiologic factors for AOB (2, 5, 9). Furthermore, abnormal perioral muscle function is believed to contribute, at least in part, to most dental open bites. Skeletal open bite is typically characterized by counter-clockwise rotation of the palatal plane, increased anterior facial height, and a high gonial angle (2, 9, 10).

Various treatment protocols have been proposed for managing AOB to achieve occlusal and facial harmony, as well as long-term stability (11). Several authors suggested that the most favorable time for intervention is during the transition from primary to mixed dentition, as this period may optimize treatment outcomes and stability (2, 12). Early treatment modalities include fixed or removable palatal cribs and bonded spurs, often

¹ Department of Dentofacial Orthopedics, Faculty of Dental Medicine, University of Mohammed V, Rabat, Morocco.

*Corresponding Author: Ousli Houda
Email: ouslihouda18@gmail.com

Accepted: 3 October 2025. Submitted: 4 May 2025.



combined with high-pull headgear or a chin cup, particularly in patients with a vertical growth pattern (13, 14).

Several studies (4, 11, 15, 16) have investigated the use of crib therapy in the early management of open bite. The palatal crib helps eliminate tongue thrusting and habits such as thumb or pacifier sucking (5). Additionally, it prevents the tongue from resting against the maxillary incisors, facilitating the correction of AOB (17, 18). According to a systematic review with a meta-analysis, crib therapy effectively improves AOB in growing patients, with an average overbite increase of approximately 3 mm (11).

Ensuring the long-term stability of orthodontic treatment outcomes remains a considerable challenge, mainly due to relapse factors such as unfavorable vertical growth patterns and the recurrence of parafunctional habits and dysfunctions. Furthermore, the palatal crib does not actively retrain tongue posture, which increases the risk of AOB relapse (19). Therefore, myofunctional therapy is required in combination with orthodontic appliances to establish proper neuromuscular patterns, correct abnormal functional postures, and return the tongue to its normal position (17).

Preserving the post-treatment stability of AOB correction remains a major challenge for orthodontists. Although several treatment modalities exist, there are some concerns and limited evidence regarding their long-term effectiveness. Therefore, this study aimed to perform a systematic review to evaluate the long-term stability of crib appliance treatment in patients with AOB.

Materials and methods

This systematic review was conducted using the PRISMA (Preferred Reporting Items for Systematic Review and Meta-Analysis) guidelines (20). Searches were performed in the Scopus, PubMed, Cochrane, ScienceDirect, and Web of Science databases. The review was registered in the PROSPERO database under the registration number CRD42024552958.

Eligibility criteria

The PICOS framework (Population, Intervention, Comparison, Outcome, and Study design) was used to define the eligibility criteria:

Population: Patients in mixed dentition who received early open bite treatment with a palatal crib

Intervention: Early treatment of an open bite with a crib appliance

Comparison: Patients treated with other orthodontic methods or those without any orthodontic treatment

Outcome: Stability or relapse of open bite following crib appliance treatment

The study selection criteria included peer-reviewed journal articles, with no date restrictions. Eligible studies involved mixed dentition patients diagnosed with AOB, defined by fully erupted central incisors and an overbite of less than 0 mm. The included studies should have a minimum follow-up of one year and evaluate the use of the crib appliance either alone or combined with other appliances. Exclusion criteria were case reports, reviews, expert opinions, animal or in vitro studies, and patients who had begun fixed orthodontic treatment or undergone dental extractions.

Search strategy

A comprehensive literature search was conducted in December 2024 in PubMed, Web of Science, Scopus, and ScienceDirect, and the Cochrane Library using a combination of MeSH terms relevant to the research question. The search strategy included the following terms: open bite AND crib AND stability OR relapse. No restrictions were applied regarding the date of publication; however, only articles published in English were included. Grey literature, conference proceedings, and clinical trial registries were not included in the search.

Study selection and data extraction

Systematic searches were executed by one author (H.O.). Two independent reviewers (H.O. and H.B.) screened the titles and abstracts of all records. Studies that passed this initial screening were then reviewed in full text by the same reviewers to assess their eligibility based on the PICOS criteria. Any disagreements were resolved through discussion with other authors. Data extraction was performed using a detailed table in Microsoft Excel 2021, including information on authors, publication year, study design, population, intervention, comparison, and outcomes.

Risk of bias

The risk of bias in the selected studies was assessed following Cochrane guidelines using the RoB 1 tool for randomized trials (21) and the Newcastle-Ottawa Scale (NOS) for non-randomized trials (22).

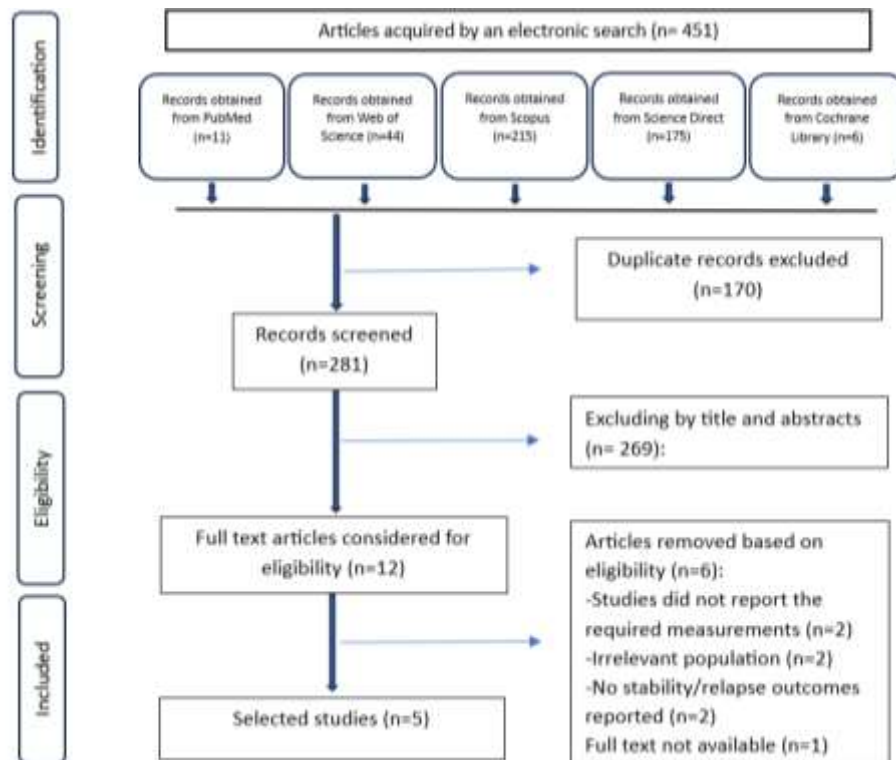


Figure 1. PRISMA flowchart

Data analysis

Due to substantial heterogeneity among the included studies, in terms of treatment protocols, study populations, and follow-up duration, a quantitative meta-analysis was not feasible.

Results

Study selection

The electronic search identified 451 records across PubMed, Scopus, Web of Science, ScienceDirect, and Cochrane Library. After removing duplicates ($n = 170$), 281 records were screened by title and abstract, of which 269 were excluded. Twelve full-text articles were assessed for eligibility. Among these, six were excluded due to the absence of required measurements, irrelevant populations, and lack of stability or relapse data. One additional study meeting the criteria was excluded because the full text could not be retrieved. Ultimately, five studies were included in the qualitative synthesis.

The selection process is shown in the PRISMA flow diagram (Figure 1).

Study characteristics

Of the five studies included in the final analysis, three were prospective non-randomized clinical studies (23–25), one was a retrospective cohort study (26), and one was a randomized clinical trial (3).

Risk of bias

Among the five studies, one was an RCT (3) and was rated as having a medium risk of bias (Table 1). The non-randomized clinical trials (nRCTs) scored between 5 and 8 on the NOS, indicating medium to high quality (23–26). Overall, the methodological quality of the evidence was moderate (21–24). The most common limitations across studies were related to the non-randomized designs, which may have introduced selection bias, and a general lack of blinding, which may have influenced outcome assessment (Table 2).

Table 1. Risk of bias assessment of RCTs using the ROB-2 tool

Studies	Criteria							Overall
	Sequence generation	Allocation concealment	Blinding	Incomplete outcome data addressed	Outcome reporting	Free of other bias	Risk of bias	
Dias et al. 2021	Unclear	Unclear	Low	Low	Low	Low	Low	Medium

Table 2. Risk of bias assessment of nRCTs using the NOS tool

Criteria/Studies		Ferreira et al., 2012	Mucedero et al, 2013	Cozza et al, 2007	Barone et al, 2024
Selection 0-4	Representativeness of the exposed cohort	-	-	*	*
	Selection of the non- exposed cohort	*	-	-	*
	Ascertainment of exposure	*	*	*	*
	Demonstration that outcome of interest was not present at start of study	-	-	-	*
Comparability 0-2	Comparability of cohorts on the basis of the design or analysis controlled for confounders	*	*	*	*
Outcome 0-3	Assessment of outcome	*	*	*	*
	Was follow- up long enough for outcomes to occur?	*	*	*	*
	Adequacy of follow- up of cohorts	*	*	*	*
Score total		6	5	6	8

Table 3 summarizes the results of the included studies regarding the stability of early open bite treatment using a crib appliance. The sample size of the studies ranged from 32 to 99, totaling 309 participants, with a mean age between 7 and 12 years. Pre-treatment open bite measurements varied from -4.4 mm to -1.56 mm, while post-treatment overbite ranged from 0.9 mm to 2.4 mm in the crib appliance groups. However, Cozza et al. (23) did not report post-treatment overbite. Three studies specified that the open bite had a dentoskeletal origin (23, 25, 26), whereas the others did not clarify the type.

Different types of orthodontic appliances were used in the studies, including fixed and removable palatal cribs

(3), palatal crib in a removable appliance combined with a chin cup (24), Quad-helix crib appliance (23, 25), and rapid maxillary expander with crib appliance (26). The crib appliance was used alone in one study (24), while in others it was combined with additional devices (23-26).

Three studies evaluated the fixed form of the crib appliance (23, 25, 26), one focused on the removable form (24), and one compared fixed and removable forms to other devices (3). This variability in treatment protocols may have affected the comparability of outcomes.

The included studies reported follow-up periods ranging from 12 months to 5 years. In this review,

Table 3. Characteristics of the studies included in the review

Author, Year	Study type	Characteristics	Population	Age	Initial open bite	Appliance used	Treatment time	Overbite after treatment	Follow-up time	Overbite post follow-up	Stability rate
Cozza et al., 2007	nRCT (Prospective)	- Angle class I, class II, and class III malocclusion	15 female, 6 male,	8.4 ± 1.5	-2,4 ± 2 mm	Quad-helix crib appliance	1.5 years +/- 7 months	2 mm	2 years	1,7 mm	85 %
Ferreira et al., 2012	nRCT (Prospective)	- Angle class I malocclusion	13 female, 6 male	8.78	- 4,07 mm	removable crib appliance combined with a high-pull chin cup	12 months	0,94 mm	15 months	1,5 mm	95%
Mucedero et al., 2013	nRCT (Prospective)	- Angle class I malocclusion	17 female, 11 male	8.2 ± 1.3	-3,3 mm	Quad-helix crib appliance	2 years	0,9 mm	5 years	1,6 mm	93%
Dias et al., 2021	Randomized clinical trial	-Angle class I malocclusion	Fixed palatal crib: 21 Removable palatal crib: 16	Fixed palatal crib: 11.44 Removable palatal crib: 11.67	Fixed palatal crib: -3,06 mm Removable palatal crib: -3,50 mm	- Fixed palatal crib - Removable palatal crib	Not mentioned	Fixed palatal crib: 1,08 mm Removable palatal crib: - 0,4 mm	2 years	Fixed palatal crib: 1,23 mm removable palatal crib: 0,73 mm	Fixed palatal crib: 90.5% Removable palatal crib: 93.75%
Barone et al., 2024	nRCT retrospective cohort study	-Class II malocclusion	14 female, 2 male	7.5 ± 0.5	-2.9 ± 1.1	Rapid maxillary expander with a crib	12 months	1.5 ± 0.6	5 years	1.8 ± 0.6	100%

follow-up was classified as short-term (12 months post-treatment) and long-term (5 years post-treatment).

Clinical findings

Removable crib appliance combined with a high-pull chin cup

In the study by Ferreira et al. (24), the initial post-treatment mean overbite was -2.66 mm in the control group and 0.94 mm in the treated group, representing a statistically significant difference. After a 15-month follow-up, the mean overbite in the control group increased by 1.39 mm, while the treated group showed a mean increase of 0.56 mm ($P = 0.10$). Clinical improvement was observed in 12 of the 19 patients. Seven patients showed a reduction in overbite, and only one experienced relapse to AOB (initial post-treatment overbite: 0.7 mm; final overbite: -0.7 mm). The overall stability rate was estimated at 95% (24).

Quad-helix crib appliance

In the study of Cozza et al. (23), the patients received active treatment for 1.5 ± 7 months. After a 2-year post-treatment follow-up, the treated group demonstrated a stability rate of approximately 85%, with a mean overbite improvement of 4.1 mm in the treated group compared to 1.4 mm in the control group.

Similarly, Mucedero et al. (25) reported favorable outcomes after a 5-year follow-up. The participants used the quad-helix crib appliances for at least 12 months, with a mean duration of 1.5 ± 0.4 years. In the treatment group, the mean overbite increased by 4.9 mm, with a stability rate of approximately 93%. In the control group, the mean overbite increase was 2.8 mm, with spontaneous AOB correction observed in 15 subjects (70%). Compared to controls, the treated group showed a greater overbite increase (2.1 mm), a reduction in overjet (~ 1.5 mm), a downward rotation of the palatal plane ($\sim 1.8^\circ$), and a decrease in the ANB angle (~ 1) (25).

Fixed palatal crib and removable palatal crib

Dias et al. (3) compared four appliances, including bonded lingual spurs, chin cup, fixed palatal crib, and removable palatal crib, used for approximately one year in treating early AOB. All appliances were effective with a mean post-treatment overbite improvement of 1.15 mm. Two years after treatment, clinically significant relapse occurred in three patients (4.76%) who had initially shown positive results (two in the fixed palatal crib group and one in the removable palatal crib group), while the rest maintained stable overbite. During the stability phase, both the fixed and removable palatal crib

groups showed greater relapse in the inclination and position of the maxillary and mandibular incisors, likely due to appliance removal and tongue pressure on the incisors (3).

Rapid maxillary expander with a crib appliance

Barone et al. (26) reported a mean overbite increase of 4.4 mm following maxillary expansion combined with a crib appliance. After a 5-year follow-up, the mean increase reached 4.81 ± 0.96 mm, with no evidence of relapse. Significant improvements in overbite were observed at both the 12-month and 5-year follow-ups compared to the control group. Additionally, the treatment group showed a consistent reduction of approximately 2.0° in the maxillomandibular angle at both time points (26).

Discussion

This systematic review found that the crib appliance, used alone or with other devices, contributes to favorable skeletal and dental stability in the correction of AOB, with stability rates exceeding 85%. Cozza et al. (23) reported an 85% stability rate, indicating the proportion of patients who maintained a positive overbite two years after treatment. During the follow-up period, an improvement of 2.7 mm in overbite was noted compared to the control group. Mucedero et al. (25) observed 93% stability at five years, with a mean overbite increase of 4.2 mm in the treated group versus 2.8 mm in controls. This correction was observed in 26 patients, with a higher stability rate than that of the control group, which showed a rate of 70%. Furthermore, Barone et al. (26) reported long-term stability in patients treated with a rapid maxillary expander combined with a palatal crib, showing a 4.8 mm overbite increase at the end of the retention phase. In contrast, the control group exhibited only a minor improvement of approximately 2.3 mm over the same 5-year period.

AOB is frequently associated with maxillary transverse constriction. Transverse correction addresses the width deficiency and produces beneficial indirect effects on vertical and sagittal maxillomandibular relationships. These include widening the maxillary arch to improve tongue posture by reducing anterior thrust, compensating for any temporary worsening of the open bite during expansion, and decreasing maxillomandibular divergence in the long term. Such changes contribute to more durable overbite improvement (15, 27, 28). In three studies (23, 25, 26), the authors combined the crib appliance with a quad-

helix or rapid maxillary expander to address the frequent co-occurrence of AOB and maxillary constriction, which often requires expansion. This approach corrects AOB by eliminating habits like thumb or tongue sucking. It also promotes maxillary expansion, which helps functional rehabilitation in growing patients. However, correction of the transverse dimension via rapid maxillary expansion (RME) can initially lead to a temporary increase in open bite due to downward movement of the maxilla during midpalatal separation and the resultant backward rotation of the mandible. This may worsen the anterior open bite in the short term before compensatory mechanisms, such as orthodontic treatment or natural dentoalveolar adaptation, help closure. This temporary bite opening is often reduced when RME is combined with crib appliances, as the crib prevents anterior tongue thrust and supports vertical control during expansion (29, 30).

Most studies reported suitable stability rate values following AOB correction. Ferreira et al. (24) reported a 95% stability rate following early AOB treatment using a removable crib appliance combined with a high-pull chin cup. At the 15-month follow-up, treatment effects were maintained, with an average overbite increase of 0.56 mm and improvement in 12 of 19 patients. However, seven patients showed a reduction in overbite, and one patient experienced relapse, with overbite decreasing from 0.7 mm to -0.7 mm in the final follow-up period. The authors attributed this relapse to the loss of the appliance's corrective effect on tongue posture. Similarly, Dias et al. (3) found that all evaluated appliances (bonded spurs, chin cup, fixed palatal crib, and removable palatal crib) achieved a 94% stability rate after two years, with an average post-treatment overbite improvement of 1.15 mm. Significant relapse, resulting in negative overbite, occurred in two patients in the fixed palatal crib group and one in the removable palatal crib group. In contrast, Cozza et al. and Mucedero et al. (23, 25) did not report the number of patients who experienced relapse. Moreover, Barone et al. (26) reported the highest success rate, as all patients maintained correct overbite at follow-up.

Current evidence does not show consistent differences in treatment stability between fixed and removable crib appliances. Barone et al. (26) reported a 100% stability rate in patients treated with a rapid maxillary expander combined with a crib. Mucedero et al. (25) observed a 93% stability rate, while Cozza et al. (23) found a slightly lower rate of 85%. In both Mucedero et al. and Cozza et al. studies, the fixed crib was used alongside a quad-helix appliance. For the

removable palatal crib, Ferreira et al. reported a 95% stability rate; however, the crib was combined with a chin cup, which may have affected the results. All studies used the crib appliance alongside other orthodontic devices, except for Dias et al. (3), which evaluated stability with the crib appliance alone.

Both follow-up duration and patient age are important factors influencing treatment outcomes. Longer follow-up periods enable assessment of long-term stability and potential relapse or continued improvement as physiological function stabilizes. Patient age reflects growth-related effects, especially after functional corrections and the resolution of parafunctional habits.

Although no clear differences in stability were observed between shorter and longer follow-up periods, formal statistical comparisons across studies were not possible, so these findings should be interpreted with caution. In Ferreira et al.'s study (24), patients were treated for 12 months and had a stability rate of 95% at 15 months. Mucedero et al. (25) observed a 93% stability rate over five years after a treatment duration of 12 months. Similarly, Barone et al. (26) reported a 100% stability rate over the same follow-up duration. These results suggest that early AOB treatment, using either fixed or removable crib appliances, provides favorable and stable outcomes in both the short and long term. Since only two studies included follow-up periods of five years or more, conclusions about long-term stability should be made cautiously.

The included studies suggest that crib appliances can produce favorable changes in the vertical skeletal pattern during AOB treatment, such as reduced maxillomandibular divergence and mandibular counterclockwise rotation, which support improved long-term stability. Barone et al. (26) reported no significant change in the maxillary position relative to the cranial base in the vertical skeletal analysis, with an average change of approximately 1.0°. In contrast, Mucedero et al. (25) observed a clinically significant 2° clockwise rotation of the palatal plane at the end of active treatment compared to controls. These findings are consistent with those of Cozza et al. (23), who reported a significant 1.8° downward inclination of the palatal plane following quad-helix crib appliance therapy. All three studies reported a notable reduction in the maxillomandibular angle. Cozza et al. (23) observed a 2.5° reduction at follow-up, Mucedero et al. (25) reported a 2.2° decrease, and Barone et al. (26) recorded a 2° improvement at both the first and second follow-ups. These findings indicate a consistent trend toward vertical skeletal improvement across studies.

On the sagittal plane, Mucedero et al. (25) reported significant improvements, including a 1.3° decrease in the ANB angle and a 1.5 mm reduction in overjet following quad-helix crib appliance therapy. These changes may result from the indirect skeletal effects of the appliance, which addresses both AOB and associated transverse maxillary constriction. In contrast, other studies found no statistically significant differences in these parameters between treated and control groups at various time points. Overall, the included studies (23, 25, 26) suggest that transverse correction contributes to open bite closure and may support treatment stability through indirect skeletal effects. However, these conclusions are based on individual study reports rather than a direct analysis across studies.

Ferreira et al. (24) observed a small molar extrusion (0.14 mm) during the post-treatment phase following use of a removable crib appliance combined with a high-pull chin cup. This minor downward movement of the posterior teeth may contribute to relapse. Similarly, Cassis et al. (31) reported molar extrusion after treatment of AOB with bonded spurs and a high-pull chin cup. After appliance removal, factors such as the absence of the restrictive vertical force provided by the appliance, continued natural vertical growth of posterior teeth in mixed dentition patients, and incomplete re-education of tongue posture and function may lead to this slight extrusion of the posterior teeth.

A main limitation in this review is the significant heterogeneity in treatment protocols among the included studies. Interventions varied from using crib appliances alone to combinations with maxillary expansion or chin cup therapy. This variability complicates direct comparisons and may explain inconsistencies in overbite improvement and stability. This overlap of interventions makes it difficult to isolate the specific effects of the crib appliance, and the lack of standardized protocols limits the generalizability of the findings. Additionally, the current literature is constrained by an insufficient number of randomized controlled trials and limited long-term follow-up data.

Future research should adopt standardized treatment protocols, involve larger patient cohorts and longer follow-up periods, and focus on consistent cephalometric and clinical outcome measures to enhance the reliability and comparability of findings.

Conclusions

This systematic review suggests that crib appliances, especially when combined with adjunctive devices like

quad-helix, achieve high rates of long-term stability in correcting AOB during mixed dentition. However, these findings are based on individual studies and should be interpreted cautiously, as the specific contribution of the crib appliance alone cannot be determined.

Acknowledgements

None.

Conflicts of interest

The authors declare that there are no conflicts of interest regarding the publication of this manuscript.

Ethical considerations

As this study is a systematic review of previously published data, no ethical approval or informed consent was required.

Author contributions

H.O. and A.H. conceptualized and designed the study. H.O. and H.B. contributed to the literature review and data collection. F.Z. supervised the study. All authors contributed to the analysis, interpretation, and drafting of the manuscript and approved the final version.

Funding

None.

References

1. Canuto LFG, Janson G, de Lima NS, de Almeida RR, Cançado RH. Anterior open-bite treatment with bonded vs conventional lingual spurs: A comparative study. *Am J Orthod Dentofacial Orthop.* 2016;149(6):847-855.
2. Lone IM, Zohud O, Midlej K, Paddenberg E, Krohn S, Kirschneck C, et al. Anterior open bite malocclusion: from clinical treatment strategies towards the dissection of the genetic bases of the disease using human and collaborative cross mice cohorts. *J Pers Med* 2023;13(11):1617.
3. Dias FA, Oltramari PVP, Almeida MRd, Conti ACdCF, Almeida RRd, Fernandes TMF. Stability of early anterior open bite treatment: a 2-year follow-up randomized clinical trial. *Braz Dent J* 2021;32:116-126.
4. Rossato PH, Fernandes TMF, Urnau FDA, de Castro AC, Conti F, de Almeida RR, et al. Dentoalveolar effects produced by different appliances on early treatment of anterior open bite: a randomized clinical trial. *Angle Orthod* 2018;88(6):684-691.
5. Artese F, Fernandes LQP, de Oliveira Caetano SR, Miguel JAM, editors. Early treatment for anterior open bite: Choosing adequate treatment approaches. *Semin Orthod* 2023;22(2):207-215.

6. Almeida MRd, Almeida RRd, Conti ACdCF, Navarro RdL, Correa GdO, Oliveira CA, et al. Long-term stability of an anterior open-bite malocclusion treated in the mixed dentition: a case report. *J Appl Oral Sci* 2006;14(6):470-475.
7. Costa JC, Fontenele GV, Syed JR, Alves J, Fernandes NMSP. Classifications and Etiologies of Open Bite: A Review. *Brazilian J Dent Oral Radiol* 2025;4(1):bjd58.
8. Yousif ASF, Hassan AFF, Idress LTMA, Elhassan IK, Elnour R, Omer EAMS, et al. Early Orthodontic and Orthopedic Interventions for Anterior Open Bite in the Mixed Dentition: A Systematic Review. *Cureus* 2025;17(11).
9. Wajid MA, Chandra P, Kulshrestha R, Singh K, Rastogi R, Umale V. Open bite malocclusion: An overview. *J Oral Health Craniofac Sci* 2018;3(3):11-20.
10. Kim K, Choy K, Park Y-C, Han SY, Jung H, Choi YJ. Prediction of mandibular movement and its center of rotation for nonsurgical correction of anterior open bite via maxillary molar intrusion. *Angle Orthod* 2018;88(5):538-544.
11. Feres MFN, Abreu LG, Insabralde NM, de Almeida MR, Flores-Mir C. Effectiveness of open bite correction when managing deleterious oral habits in growing children and adolescents: a systematic review and meta-analysis. *Eur J Orthod* 2017;39(1):31-42.
12. Carneiro GU, Carreira DGG, Conti ACdCF. Stability of anterior open bite treatment with bonded spurs in the mixed dentition: a longitudinal follow-up. 2025.
13. Almugla YM, Shekhar MG. Does Early Orthodontic Treatment in Mixed Dentition Improve Long-Term Outcomes? A Systematic Review and Meta-Analysis. *Medicina* 2025;61(10):1854.
14. Alawy SB, El-Desouky SS, Kabbash IA, Hadwa SM. Effects of tongue tamers and customized bonded spurs as an early treatment of anterior open bite: a randomized clinical study. *BMC Oral Health* 2025;25(1):76.
15. Mousa MR, Hajeer MY, Farah H. Evaluation of the open-bite Bionator versus the removable posterior bite plane with a tongue crib in the early treatment of skeletal anterior open bite: A randomized controlled trial. *J World Fed Orthod* 2021;10(4):163-171.
16. Meng M, Xie Y, Cao J, Yu Y, Zhou X, Zou J. Effects of bonded spurs, fixed and removable palatal crib in the early treatment of anterior open bite: A systematic review and meta-analysis. *Am J Orthod Dentofacial Orthop* 2023;163(3):298-310.
17. Van Dyck C, Dekeyser A, Vantricht E, Manders E, Goeleven A, Fieuws S, et al. The effect of orofacial myofunctional treatment in children with anterior open bite and tongue dysfunction: a pilot study. *Eur J Orthod* 2016;38(3):227-234.
18. Cozza P, Baccetti T, Franchi L, McNamara Jr JA. Treatment effects of a modified quad-helix in patients with dentoskeletal open bites. *American Am J Orthod Dentofacial Orthop* 2006;129(6):734-739.
19. Asiry MA. Anterior open bite treated with myofunctional therapy and palatal crib. *J Contemp Dent Pract* 2015;16:243-247.
20. Page MJ, McKenzie JE, Bossuyt PM, Boutron I, Hoffmann TC, Mulrow CD, et al. The PRISMA 2020 statement: an updated guideline for reporting systematic reviews. *bmj* 2021;372.
21. Higgins JP, Altman DG, Gøtzsche PC, Jüni P, Moher D, Oxman AD, et al. The Cochrane Collaboration's tool for assessing risk of bias in randomised trials. *bmj* 2011;343.
22. Luchini C, Stubbs B, Solmi M, Veronese N. Assessing the quality of studies in meta-analyses: Advantages and limitations of the Newcastle Ottawa Scale. *World J Metaanal* 2017;5(4):80-84.
23. Cozza P, Mucedero M, Baccetti T, Franchi L. Treatment and posttreatment effects of quad-helix/crib therapy of dentoskeletal open bite. *Angle Orthod* 2007;77(4):640-645.
24. Ferreira FPC, Almeida RRd, Torres FC, Almeida-Pedrin RRd, Almeida MRd, Santana Filho R. Evaluation of the stability of open bite treatment using a removable appliance with palatal crib combined with high-pull chincup. *Dental Press J Orthod* 2012;17:52-60.
25. Mucedero M, Franchi L, Giuntini V, Vangelisti A, McNamara Jr JA, Cozza P. Stability of quad-helix/crib therapy in dentoskeletal open bite: a long-term controlled study. *Am J Orthod Dentofacial Orthop* 2013;143(5):695-703.
26. Barone S, Bennardo F, Diodati F, Salviati M, Calabria E, Colangeli W, et al. Short-and Long-Term Effects of Maxillary Expander with Tongue Crib in Growing Open-Bite and Skeletal Class II Patients: A Retrospective Study. *Dent J* 2024;12(2):22.
27. Lione R, Cozza P, Pavoni C, Franchi L, Fusaroli D, Mucedero M. Long-term evaluation of rapid maxillary expansion and bite-block therapy in open bite growing subjects. *Angle Orthodontist*. 2018;88(5):523-529.
28. Teixeira RAN, Ferrari Junior FM, Garib D. Influence of rapid maxillary expansion in the stability of anterior open bite treatment. *Clin Oral Investig* 2022;26(10):6371-6378.
29. Chhutani P, Deshmukh S, Jethi S, Agarkar S, Yerawadekar S, Rahalkar J. Effect of rapid maxillary expansion on mandibular rotation—A systematic review. *J Indian Orthod Soc* 2020;54(1):5-13.
30. Patil GV, Lakhe P, Niranjane P. Maxillary expansion and its effects on circummaxillary structures: a review. *Cureus* 2023;15(1).
31. Cassis M, de Almeida R, Janson G, Aliaga-Del Castillo A, de Almeida M. Stability of anterior open bite treatment with bonded spurs associated with high-pull chincup. *Orthod Craniofac Res* 2018;21(2):104-111.