

# Simultaneous endodontic and surgical management of skin dimpling due to an old sinus tract: a case report

Moein Khojaste<sup>1</sup>, Sahand Samieirad<sup>2</sup>, Navid Kazemian<sup>2</sup>, Sara Navabi<sup>3</sup>

## Abstract

**Objective:** Management of a skin dimpling due to a chronic periapical lesion may pose challenges. This case report presents a multidisciplinary approach to resolving a persistent cutaneous scar of endodontic origin and also offers a flowchart for the management of similar cases.

**Case report:** A 34-year-old female referred to the Endodontics Department of Mashhad Dental School at Mashhad University of Medical Sciences, complained of a skin dimpling on her face with a history of pus discharge. Diagnostic workup and radiographic examination revealed that the right mandibular first molar had a failing root canal treatment and a defective restoration. The respective tooth underwent endodontic retreatment. Due to palpation of a cord-like tract at the apical region of the tooth, surgical removal of the mentioned structure was planned using a mucoperiosteal flap. After flap elevation, the cord was cut at the base of attachment to the bone, which resulted in immediate correction of facial contour. Finally, the tooth was permanently restored. At the 6-month follow-up visit, the periapical lesion was healing, and the face had a normal contour.

**Conclusions:** Considering the significance of surgical intervention in cases with a cord-like sinus tract and consequent skin dimpling, a flowchart for a step-by-step decision-making process is offered to better restore the normal facial contour.

**Keywords:** Cutaneous fistula, Differential diagnosis, Endodontic, Periapical abscess, Surgical treatment, Sinus tract

## Introduction

Cutaneous sinus tracts of odontogenic origin are a consequence of an incorrect diagnosis, inappropriate treatment plan, or endodontic failure (1). Extraoral sinus tracts are less common compared to intraoral sinus tracts. Many patients with cutaneous sinus tracts are not aware of their dental problems. Specific dental signs and symptoms do not always manifest in many cases. As a result, patients do not often primarily seek dental treatment, and refer to physicians to receive treatments such as antibiotic therapy, laser, and surgery. However, recovery does not occur until the odontogenic cause is identified and eliminated (2).

Several case reports are available regarding extraoral sinus tracts of odontogenic origin. In the majority of these cases, the patient's chief complaint was the presence of a cutaneous fistula with occasional drainage. In such cases, finding the causative tooth, and endodontic treatment of the infected tooth (if restorable) or its extraction (if not restorable), without surgical removal of the fistula, resolves the problem with/without scarring (3). The remaining scar tissue can be removed by dermatological procedures such as fractional laser therapy (4).

The presence of skin dimpling (deep cutaneous depression) without a drainage path has rarely been reported. Skin dimpling occurs due to fibrosis of the path of a chronic, old cutaneous fistula and the resultant tension on the skin. In such cases, treatment of the etiological tooth and dermatological interventions alone cannot treat the cutaneous lesion, and surgical removal of the cord-like tract may be required (5).

This case report describes the surgical management of a case presenting skin dimpling of odontogenic origin and offers a flowchart for treatment planning in cases with a cutaneous fistula.

## Case Report

This study was approved by the Research and Ethics Committee of Mashhad University of Medical Sciences (IR.MUMS.REC.1401.056).

<sup>1</sup>Department of Periodontics, School of Dentistry, Mashhad University of Medical Sciences, Mashhad, Iran.

<sup>2</sup>Department of Oral and Maxillofacial Surgery, School of Dentistry, Mashhad University of Medical Sciences, Mashhad, Iran.

<sup>3</sup>Department of Endodontics, School of Dentistry, Mashhad University of Medical Sciences, Mashhad, Iran.

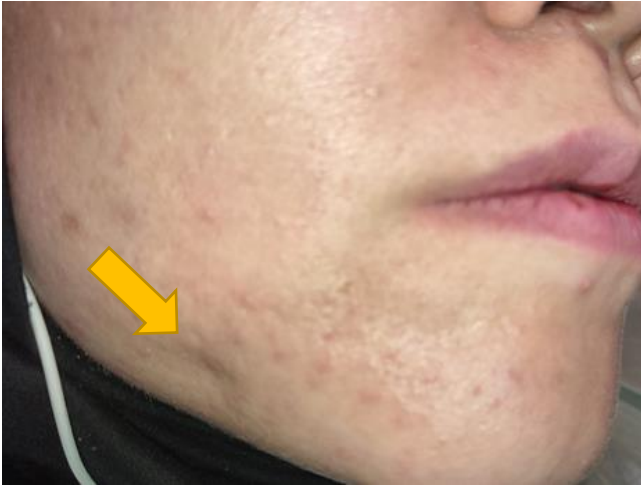Corresponding Author: Sara Navabi  
Department of Endodontics, School of Dentistry, Mashhad University of Medical Sciences, Mashhad, Iran.

Email: Navvabis981@mums.ac.ir

Accepted: 27 December 2022. Submitted: 16 September 2022.

DOI: [10.22038/JDMT.2023.67877.1536](https://doi.org/10.22038/JDMT.2023.67877.1536)



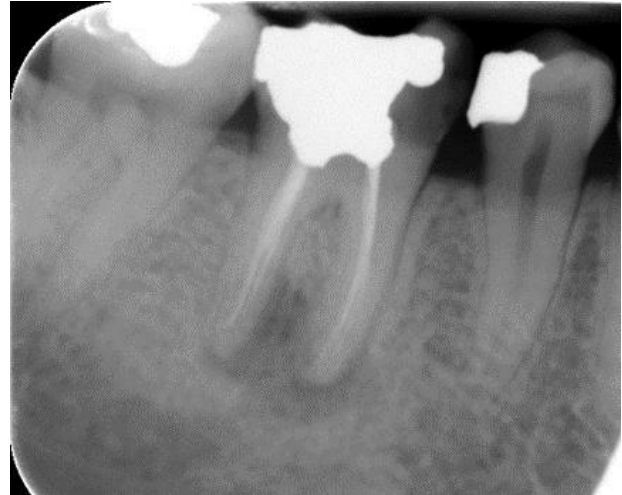

**Figure 1.** A pre-operative view of the scar (dimpling) marked by the yellow arrow

A 34-year-old healthy female with no systemic disease was referred to the Endodontics Department of Mashhad Dental School at Mashhad University of Medical Sciences, complaining of a skin dimpling on her right cheek (Figure 1). Upon taking the patient's history, it was revealed that she had a history of endodontic treatment of her right mandibular first molar in a private dental office two years earlier. The patient could not recall whether the skin dimpling appeared before or after the endodontic treatment. There was no drainage path on the skin, but the patient recalled a history of drainage in the past. Pulpal and periapical tests were performed for all of the teeth in the right mandibular quadrant. The right mandibular first molar had a brief dull pain on percussion and had a defective restoration. The remaining teeth exhibited a normal response. Palpation of the gingiva around the tooth revealed a cord-like drainage path in the vestibular depth at the site of the right mandibular first molar.

A periapical radiograph was obtained. The radiograph revealed a periradicular lesion around the mandibular first molar roots and the poor quality of endodontic treatment (Figure 2).

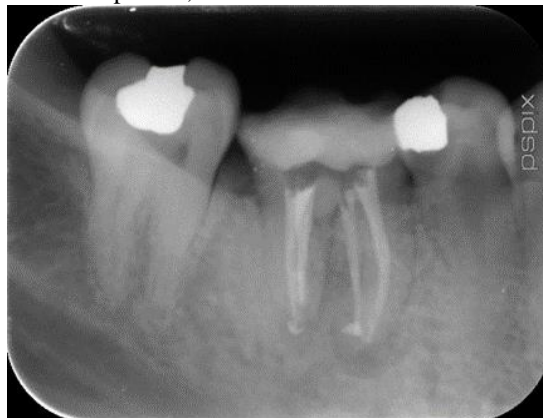The treatment plan consisting of endodontic retreatment of the right mandibular first molar and surgical removal of the cord-like tract was explained to the patient, and



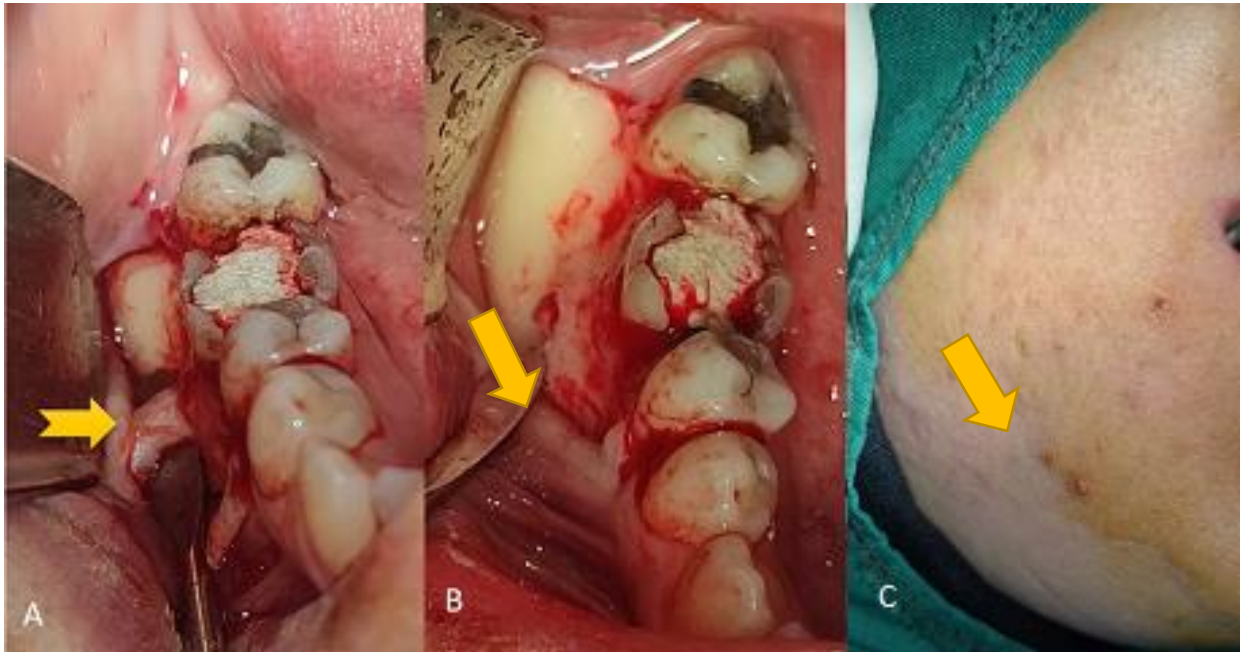
**Figure 2.** A pre-operative periapical radiograph showing poor quality of endodontic treatment and a defective restoration

written informed consent was obtained. Endodontic retreatment was initiated with D RaCe files (FKG Dentaire, La Chaux-de-Fonds, Switzerland) and chloroform (Nik Darman, Tehran, Iran). Irrigation was done with 5.25 % sodium hypochlorite (Cerkamed, Stalowa Wola, Poland), under ultrasonic activation throughout the procedure. The root canals were then obturated with gutta-percha and AH-Plus sealer (Dentsply/De Trey, Konstanz, Germany) with a warm vertical condensation technique. The treatment was accomplished within one session (Figure 3). After endodontic retreatment, the patient was referred for surgical treatment. A mucoperiosteal flap was reflected to the root apex under local anesthesia with 1.8 mL of 2% lidocaine with 1:100,000 epinephrine (DarouPakhsh, Tehran, Iran). The cord-like tract attached to bone was visualized in the apical region (Figure 4 A and B). The attachment to bone was cut, which resulted in immediate relaxation of skin, and resumption of normal facial contour (Figure 4 C). The tract was completely removed and sent for histopathological analysis. The pathology report revealed that the tract had an epithelial origin.

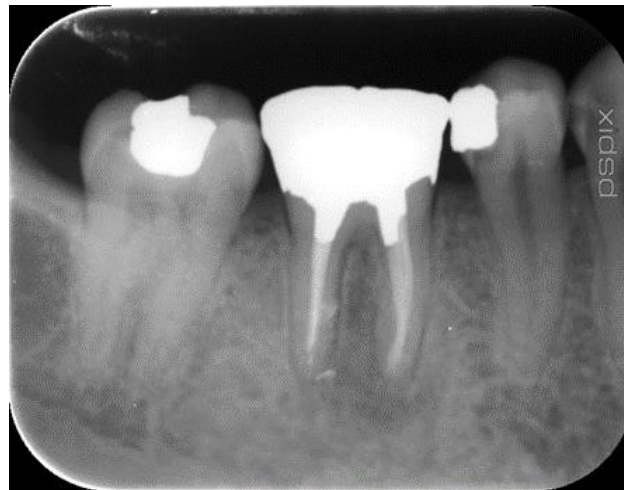The patient was referred for definitive restoration 2 weeks after surgery. At the 6-month follow-up visit, periradicular healing was noted (Figure 5), and the facial skin had a normal contour.



**Figure 3.** A periapical radiograph taken immediately after endodontic treatment



**Figure 4. A and B:** The cord-like tract during the surgical procedure, marked by yellow arrow  
**C:** immediate return to the normal contour mid-surgery



**Figure 5.** A periapical view at an 8-month follow-up

## Discussion

The diagnosis of cutaneous sinus tracts of odontogenic origin has always been challenging due to their relatively similar appearance to skin lesions and their low prevalence. Several reports are available in this regard in the medical and dental literature (6-9).

The absence of distinct dental signs and symptoms, and patient's lack of knowledge about their dental problem often result in the prescribing of dermatological treatments or even cancer therapy by physicians. In almost all cases, the cutaneous lesion recurs due to the persistence of the odontogenic source (7, 8, 10).

In the case of active drainage, tracing with a gutta-percha or lacrimal probe reveals the source of infection, which is often a necrotic tooth or a residual root (11, 12). Also, conducting pulpal and periapical tests for the suspected tooth and the adjacent teeth can aid in a more accurate

diagnosis. Finally, periapical radiographs should be obtained with or without tracing the suspected tooth using gutta-percha (10).

The differential diagnosis often includes fungal or bacterial infections, traumatic ulcers, presence of a foreign body, neoplasms, local skin infections (carbuncle and infected epidermoid cyst), chronic tuberculosis lesion, pyogenic granuloma, osteomyelitis, gumma of tertiary syphilis, and actinomycosis. Developmental defects of thyroglossal duct origin or branchial cleft, dacryocystitis, salivary gland, and duct fistula, and suppurative lymphadenitis are among the rare entities that should also be included in the list of differential diagnosis (10). If the sinus tract does not resolve after the elimination of the primary etiology, actinomycosis would be the most probable diagnosis (7).

In some cases, especially in patients with chronic sinus tracts, palpation of the tissue around the tooth can reveal

the presence of a cord-like tract attached to the alveolar bone. This rope-like fibrous tissue can pull the skin inward and create a skin crater, which does not heal spontaneously even after the resolution of the odontogenic cause (5, 10).

According to the literature, root canal therapy is the first line of treatment for such cases showing a cord-like tract attached to the bone. To our knowledge, only one previous study has reported the surgical removal of this cord-like structure through a sulcular flap immediately after endodontic treatment of the respective tooth (5). In the remaining articles, the patient was referred to receive cosmetic surgical procedures (3, 6, 7, 9, 13) or laser therapy (4).

Strict emphasis on non-surgical treatment in many cases results in incomplete restoration of facial contour and forces the patient to seek treatments with lower efficacy. Because in many chronic cases, this cord can become considerably thick, cosmetic surgical procedures, laser therapy, or dermatological treatments may not be able to successfully resolve the skin dimpling.

In the present case, surgical removal of the cord-like tract resulted in the correction of skin dimpling and restoration of normal facial contour immediately after the procedure. The same outcome was reported by Chkoura et al (5). We provide a diagnostic step-by-step flowchart for the treatment of patients complaining of cutaneous sinus tracts (Figure 6).

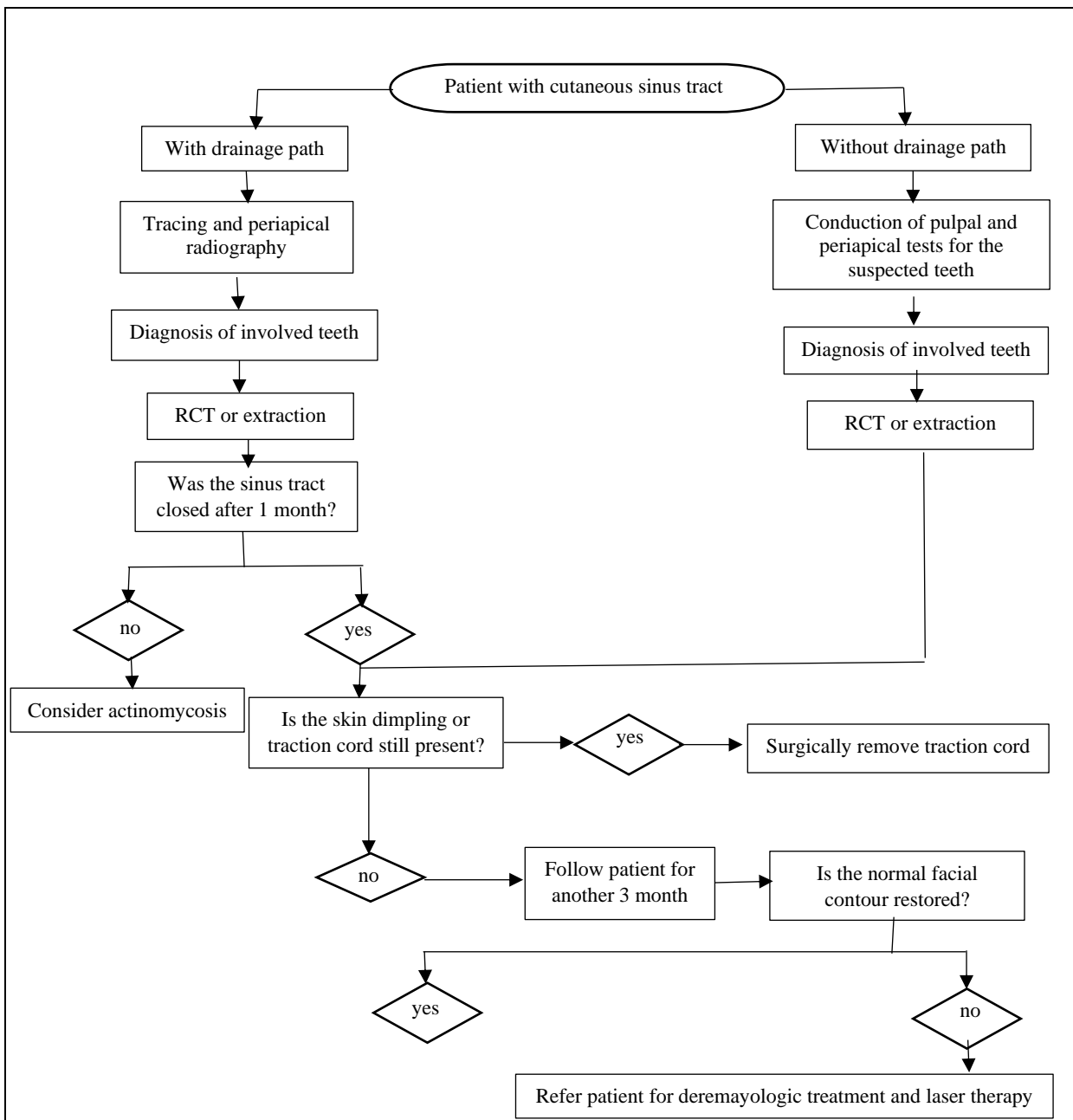


Figure 6. A suggested flowchart for the management of cutaneous sinus tracts

If the clinician elects to perform an extraoral facial surgical procedure, the dimpling may not completely resolve and the surgical scar may persist for a long time. Thus, dental clinicians should consider the identification and surgical removal of the possible cord-like tract after endodontic treatment in patients complaining of a skin sinus tract. After that, complementary dermatological treatments may be performed. Case reports as such depict the need to incorporate algorithms into decision making and subsequent treatment plans.

We suggest that each case with a cutaneous sinus tract be investigated individually to determine the best treatment modality.

## Conclusion

Cutaneous sinus tracts have been well documented in the literature. This case report highlighted the optimal efficacy of surgical treatment in the fast correction of facial contour in a case of skin dimpling caused by chronic apical periodontitis. Also, a flowchart was developed for patients with cutaneous sinus tract, with emphasis on the surgical treatment.

## Conflicts of interest

The authors deny any conflicts of interest related to this case report.

## Acknowledgements:

There was no funding associated with this paper.

## References

1. Cantatore JL, Klein PA, Lieblich LM. Cutaneous dental sinus tract, a common misdiagnosis: a case report and review of the literature. *Cutis* 2002;70(5): 264-267.
2. Johnson BR, Remeikis NA, Van Cura JE. Diagnosis and treatment of cutaneous facial sinus tracts of dental origin. *J Am Dent Assoc* 1999;130(6):832-836.
3. Cioffi GA, Terezhalmay GT, Parlette HL. Cutaneous draining sinus tract: an odontogenic etiology. *J Am Acad Dermatol* 1986;14(1):94-100.
4. Al-Obaida MI, Al-Madi EM. Cutaneous draining sinus tract of odontogenic origin. A case of chronic misdiagnosis. *Saudi Med J* 2019;40(3):292-297.
5. Chkoura A, Elwady W, Taleb B. Surgical management of a cutaneous sinus tract: a case report and review of the literature. *J Contemp Dent Pract* 2010;11(5):049-055.
6. Lewin-Epstein J, Taicher S, Azaz B. Cutaneous sinus tracts of dental origin. *Arch Dermatol* 1978;114(8):1158-1161.
7. Braun RJ, Lehman J, 3rd. A dermatologic lesion resulting from a mandibular molar with periradicular

pathosis. *Oral Surg Oral Med Oral Pathol* 1981;52(2):210-212.

8. Cohen PR, Eliezri YD. Cutaneous odontogenic sinus simulating a basal cell carcinoma: case report and literature review. *Plast Reconstr Surg* 1990;86(1):123-127.
9. McWalter GM, Alexander JB, del Rio CE, Knott JW. Cutaneous sinus tracts of dental etiology. *Oral Surg Oral Med Oral Pathol* 1988;66(5):608-614.
10. Latifa H, Dorsaf T, Amira K, Karim J, Nabiha D. Surgical management of an odontogenic cutaneous sinus tract misdiagnosed for 4 years. *Clin Case Rep* 2022;10(2):e05333.
11. Kikly A, Ajili F, N Douki N. Cutaneous Fistula of Dental Origin: How to Identify it to Better Treat It. *Med Dent Sciences* 2022;1:29-30.
12. Hodges TP, Cohen DA, Deck D. Odontogenic sinus tracts. *Am Fam Physician* 1989;40(1):113-116.
13. Kallel I, Moussaoui E, Kharret I, Saad A, Douki N. Management of cutaneous sinus tract of odontogenic origin: Eighteen months follow-up. *J Conserv Dent* 2021;24(2):223-227.