

Evaluation of middle mesial canal prevalence and morphology in mandibular molars in a Turkish population by cone beam computed tomography (CBCT)

Merve Ece Yüzer¹, Sadullah Kaya¹

Abstract

Objective: This study aimed to assess the prevalence and morphology of the middle mesial (MM) canal in the mandibular first, second, and third molars of a Turkish population using cone beam computed tomography (CBCT).

Methods: In this retrospective cross-sectional study, CBCT scans of 637 patients were analyzed. Molar teeth with complete root development and without prior root canal treatment were included, counting 2177 mandibular molars. The prevalence of isthmus and MM canal, and the morphology of the MM canals (confluent, independent, or fin-type canals) was determined in different molar groups. Data analysis was performed by the chi-square test, and the intra-observer reliability was assessed using the Kappa coefficient at a significance level of $P < 0.05$.

Results: The overall prevalence of the isthmus and MM canal in mandibular molars was 51.36% and 8.36%, respectively. The prevalence of isthmus was greatest in second molars (54.78%) and the prevalence of MM canal was highest in first molars (15.58%). A significant association was found between the prevalence of isthmus and MM canal with the type of molar tooth ($p < 0.05$), but the morphology of the MM canal was not significantly different among the molar groups ($P = 0.41$). There was no significant relationship between the presence of the MM canal and the age and gender of the participants ($P > 0.05$).

Conclusions: The MM canal is occasionally observed in mandibular molars, predominantly in the first molars, emphasizing the need for accurate diagnosis to reduce post-operative complications. The majority of identified MM canals were of the confluent type.

Keywords: Cone-beam computed tomography, Dental pulp, Endodontic treatment, Molar, Mandible

Introduction

The efficacy of endodontic treatment is critically dependent on the comprehensive identification, shaping, disinfection, and sealing of all root canals. Failing to detect even one canal might jeopardize the treatment's success since remaining necrotic tissue in such canals can create an environment for microbial proliferation (1).

Recent breakthroughs in dental technology, such as cone beam computed tomography (CBCT), micro-computed tomography, and dental operating microscopes, have facilitated in-depth examinations of root canal systems. Notably, CBCT has emerged as a game-changer, offering multiple advantages like accessibility, reduced radiation compared to traditional CT scans, and the ability to offer

detailed sectional views of the target area. As Michetti et al. (2) stated, CBCT presents a reliable, and non-invasive perspective of root canal anatomy. Through advanced three-dimensional imaging, it has become increasingly clear that root canal anatomy is complex and intricate.

The mandibular first molars have drawn considerable attention due to their recurrent need for endodontic procedures. While these molars predominantly possess two roots, the canal count within these roots can differ. Aside from the standard two canals in the mesial root, a third canal termed the middle mesial (MM) canal might exist. The diagnosis of the MM canal is important as any tissue or necrotic debris left in the space may lead to treatment failure. The occurrence of this canal in mandibular first molars has been documented to fluctuate between 0.35% and 15% in various studies (3-5). In mandibular second molars, Caliskan et al. (6) recorded a 1.96% prevalence for the presence of three canals. Mandibular third molars demonstrate diverse root canal anatomies, yet the prevalence of MM canals in these teeth is relatively under-researched.

¹ Department of Endodontics, School of Dentistry, Dicle University, Diyarbakır, Turkey.

Corresponding Author: Merve Ece Yüzer
Department of Endodontics, School of Dentistry, Dicle University,
Diyarbakır, Turkey.
Email: sadullahkaya@hotmail.com

Accepted: 17 June 2023. Submitted: 19 February 2023.

DOI: [10.22038/JDMT.2023.70819.1556](https://doi.org/10.22038/JDMT.2023.70819.1556)



The presence of an isthmus is another anatomical variation that may be observed in every dental root that contains two canals, such as mandibular molars. An isthmus is defined as a narrow pulp space extending between two main root canals and may contain tissue remnants and necrotic debris, potentially leading to root canal failure.

Anatomical deviations are pivotal determinants of the results of root canal treatments. Overlooked or untreated canals can contribute to procedure failures. Tooth anatomy can vary considerably across different populations, influenced by genetic and environmental factors (3, 7). Recognizing these variations in particular populations is vital for dental practitioners. Consequently, this study aimed to investigate the prevalence of isthmus and MM canals in mandibular molars of the Turkish population, determine the morphology of MM canals, and elucidate any associations between the presence of MM canals and the age and gender of the participants.

Materials and Methods

Study design and ethical consideration

This retrospective study was conducted following the 'Preferred Reporting Items for Laboratory Studies in Endodontology (PRILE) 2021' guidelines (8). The ethics committee of Dicle University approved this study (approval number: 2020/40), ensuring adherence to the principles outlined in the Declaration of Helsinki.

Sample selection

CBCT images from 1158 patients referred to the Department of Oral, Dental, and Maxillofacial Radiology, School of Dentistry, Dicle University between 2015 and 2020 were obtained. Only scans of patients aged 16 years and above were included. The CBCT scans of teeth with previous root canal treatments, intracanal posts, extensive restorations, root resorption or calcification, incomplete root development, and images with artifacts were excluded. Finally, 637 patients' images met the inclusion criteria, and 2177 mandibular molars (from the 637 included patients) were assessed.

Image analysis

Scans were acquired using the iCAT cone-beam computed tomography device (Model 17–19, Imaging Sciences International, Hatfield, PA, USA). This device, featuring a 360-degree rotating X-ray tube and a 0.3 mm voxel size, operated under consistent exposure parameters: 120 kV, 5 mA, 9.6 second exposure time, and 0.3 mm axial thickness. An expert endodontist

examined the scans on sagittal, axial, and coronal planes using the iCAT Vision software. No limitations were imposed on contrast, magnification, or density settings during the evaluation. To assess intra-observer consistency, the same observer re-evaluated a random sample of 10% of the images after a three-week interval.

In CBCT images, the prevalence of isthmus and MM canal and in the mesial roots of mandibular molars was determined. Isthmuses and true MM canals were identified as specific connections between the mesiobuccal (MB) and mesiolingual (ML) canals. An isthmus was defined as a narrow pulp space, extending between two main roots, whereas an MM canal was detected as a third canal between the mesiobuccal and mesiolingual canals in the mesial root. The morphology of the MM canals was categorized based on Pomeranz's classification, which classifies them into an independent canal, a canal ending in confluence with one of the main mesial canals, and a fin-type canal that facilitates inter-canal passage (7). When the MM canal converged with a primary mesial canal, the specific canal (MB or ML) was recorded.

The demographic data including the age and gender of the participants was recorded. Patients were grouped by age as follows: ≤ 20 , 21–40, 41–60, and >60 . The prevalence of isthmus and MM canal, and the morphology of MM canals were then analyzed across the first, second, and third molars, and the association between the presence of MM canal and the age and gender of the participants was determined.

Statistical analysis

Data analysis was conducted using IBM SPSS 21.0 software. The chi-square test was employed to determine relationships between variable groups. A significance level was set at 0.05. The Kappa coefficient was utilized to evaluate intra-observer reliability.

Results

In the study of 637 participants, 330 (51.81%) were females and 307 (48.19%) were males. The age range of the participants spanned from 16 to 80 years, with an average age of 32 years. When categorized by age, 160 (25.12%) were aged 20 years or below, 299 (46.94%) ranged from 21 to 40 years, 146 (22.92%) from 41 to 60 years, and 32 (5.02%) were over 60 years old.

The number of 2177 mandibular molars was assessed using 637 CBCT scans. This evaluation comprised 796 first molars, 1015 second molars, and 366 third molars. Out of these teeth, 1078 (49.51%) were situated on the left side of the mandible and 1099 (50.5%) on the right.




Figure 1. Axial CBCT sections of the isthmus in mandibular molars. A: The image of the isthmus present in the coronal third of the root, B: The image of the isthmus present in the apical third of the root.

Table 1. The presence of an isthmus in different molar groups

The presence of isthmus	First molar	Second molar	Third molar	Total	P- value
Present	398 (50%)	556 (54.78%)	164 (44.81%)	1118 (51.36%)	0.003*
Absent	398 (50%)	459 (45.22%)	202 (55.19%)	1059 (48.64%)	
Total	796 (100%)	1015 (100%)	366 (100%)	2177 (100%)	

*Values less than 0.05 indicate a significant difference between the groups based on the chi-squared test ($p < 0.05$)

The study identified the presence of an isthmus between the canals in the mesial root in 51.36% of all samples (Figure 1). The type of tooth group had a significant correlation with the presence of an isthmus ($p = 0.003$; Table 1). Specifically, an isthmus was evident in 50% of the first molars, 54.78% of the second molars, and 44.81% of the third molars.

The overall prevalence of the MM canal across all molar types was 8.36%. There was a significant association

between the presence of the MM canal and the type of molar ($P = 0.001$; Table 2). Specifically, 15.58% of first molars, 5.32% of second molars, and 1.09% of third molars had a MM canal (Table 2). The classification of MM canals did not significantly differ between the molar groups ($P = 0.41$; Table 2). Among the confluent canals, 65.22% merged with the ML canal, with no significant difference to MB or both canal types ($P = 0.052$; Table 2).

Table 2. The characteristics of middle mesial (MM) canals in different dental groups

	Subgroups	First molar	Second molar	Third molar	Total	P-value
The presence of MM canal	Present	124 (%15.58)	54 (%5.32)	4 (%1.09)	182 (%8.36)	0.001*
	Absent	672 (%84.42)	961 (%94.68)	362 (%98.91)	1995 (%91.64)	
	Total	796 (100%)	1015 (100%)	366 (100%)	2177 (100%)	
The morphology of the MM canal	Confluent	91 (%73.39)	34 (%62.96)	2 (%50)	127 (%69.78)	0.41
	Independent	27 (%21.77)	15 (%27.78)	2 (%50)	44 (%24.18)	
	Fin Type	6 (%4.84)	5 (%9.26)	0 (%0)	11 (%6.04)	
	Total	124 (100%)	54 (100%)	4 (100%)	182 (100%)	
The type of confluent canal	Mesiobuccal	24 (24.74%)	19 (48.72%)	1 (50%)	44 (31.88%)	0.052
	Mesiolingual	71 (73.2%)	18 (46.15%)	1 (50%)	90 (65.22%)	
	Both	2 (2.06%)	2 (5.13%)	0 (0.0%)	4 (2.9%)	
	Total	97 (100%)	39 (100%)	2 (100%)	138 (100%)	

*Values < 0.05 indicate a significant difference between the groups based on the chi-squared test

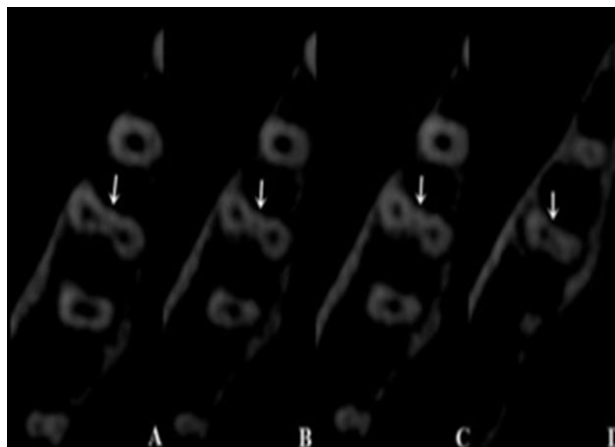


Figure 2. Different representations of the confluent mid-mesial canal, are seen in axial tomography sections (White arrows point to cross-sectional views of the mid-mesial canals)




Figure 3. Appearance of a fin-type middle mesial canal on tomography sections at different levels (White arrows point to cross-sectional views of the mid-mesial canals)

There was no significant correlation between the prevalence of MM canals and the age and gender of the participants ($p > 0.05$).

The intra-observer reliability was notably high, concerning the identification of an MM canal and its classification (Kappa values of 0.811 and 0.875, respectively; $p < 0.05$).

Discussion

The mandibular first molars are usually the first permanent teeth that erupt into the oral cavity and thus these teeth frequently require endodontic procedures, making their morphological assessment crucial (10). Extra roots and canals are among the elements that can be overlooked, leading to treatment failures. It is essential to assess the root canal system of each tooth before treatment, taking into account any morphological variations (6,7,11). There are also studies examining the number of roots and canals in mandibular second molars (6,12). The mandibular third molars have a complex anatomy (13). Yet, our literature review did not reveal any studies investigating the presence of the MM canal in mandibular third molars.

The present study assessed the MM canals' prevalence using CBCT scans. This radiographic method offers clear three-dimensional images, removing the overlay of anatomical structures seen in periapical and panoramic radiographs. CBCT scans are now routinely obtained in dentistry (14).

In this research, the MM canal's overall prevalence was 8.36%. Breaking down the presence of the MM canal in individual mandibular molars, it was found in 15.58% of the first molars, 5.32% of the second molars, and 1.09% of the third molars. Moreover, an isthmus appeared in 51.36% of all mandibular molar teeth. Specifically, the isthmus was present in the mesial roots of 50% of the first molars, 54.78% of the second molars, and 44.81% of the third molars. The prevalence of the isthmus was significantly different among the molar groups.

The presence of MM canals has been explored using various methods. Studies using microscopes reported an MM canal prevalence ranging from 1% to 37.5% (4,5,7,15,16). In CBCT studies, the MM canal prevalence in mandibular first molars ranged from 0.35% to 26% (3, 9,17,18). A study within the Chinese population indicated a 3.1% prevalence among 357 CBCT scans, a value lower than our results (29). Some researchers used

micro-CT to assess the MM canal prevalence in mandibular first molars, yielding values of 7.7% from a study with 104 extracted molars, and 18.6% from another study with 258 extracted molars (19,20). In a Turkish population, the MM canal prevalence in first molars was 14.8% using micro-CT, aligning closely with our findings (20). Variability in results across studies may be attributed to differences in investigation methods, sample sizes, and factors like participants' ethnicity, age, and gender. Additionally, studies have sometimes categorized the communications between the MB and ML canals differently, either as an isthmus or MM canal. Isthmuses are thin, ribbon-like connections between two root canals, whereas an MM canal is defined as a third canal between the MB and ML canals in the mesial root of mandibular molars (10). Due to advancements in radiographic studies, the communications between canals, especially in the mesial roots of mandibular molar teeth, have been more precisely elucidated.

In the present study, an isthmus between the canals in the mesial root was identified in 51.36% of all samples. The prevalence of an isthmus in the mesial roots of the mandibular first molars varies between 17% and 83% across studies (21,22). In a study assessing 36 mandibular first molars from the Chinese population via micro-CT, an isthmus was detected in 32 teeth within the apical 6 mm length of the mesial root (22). Mannocci et al. (21) noted that the prevalence of an isthmus within the apical 5 mm of the mandibular first molars ranged from 17.25% to 50.25%. In another study focusing on both the first and second mandibular molars, the prevalence of an isthmus in mesial roots was reported as 69.6% (16). Other research conducted on various populations has found a higher occurrence of isthmuses in the mandibular second molars than in the first molars (23,24). Our findings regarding the presence of isthmuses align with several other studies on this topic (25-27). The elevated rates observed in some micro-CT studies could be attributed to differences in examination techniques and our study's inclusion of mandibular third molars.

Previous studies reported that the prevalence of MM canals is lower in mandibular second molars than in the first molars (6, 23-28). Our results corroborate this observation. We also found that the MM canal was the least common in the third molars.

In a study by Pomeranz et al. (7), endodontic treatment was administered for 100 mandibular teeth (61 first molars and 39 second molars). The existence of an MM canal was revealed in 12 teeth. These canals were categorized into three types: 8 had a fin type, 2 exhibited a confluent type, and 2 showed an independent type of middle mesial canal. The present study also evaluated the

type of MM canals based on Pomeranz's classification. There was no significant difference between the types of MM canals across the mandibular molar teeth. The confluent MM canal was more prevalent across all molar groups (73.39% for first molars, 62.96% for second molars, and 50.0% for third molars). Conversely, the fin-type MM canal was the least common in each group (4.84% for first molars, 9.26% for second molars, and 0% for third molars). Our study rates differ from those in Pomeranz's research, which could be due to our larger sample size, and the examination method.

There is a limited number of studies in the literature that link patients' gender to MM canal characteristics. The reason might be the inability to determine gender from extracted teeth and the overall scarcity of studies on MM canals. In this research, gender did not have a statistically significant correlation with the prevalence of the MM canal. This is consistent with another study that mentioned no association between gender and the prevalence of the MM canal (29).

In the present study, participants were categorized into four age groups: ≤ 20 , 21-40, 41-60, and >60 years. No significant association was observed between age and the prevalence of the MM canal. The relationship between age and the prevalence of the MM canal remains ambiguous. Some researchers suggest that MM canals are more frequently observed in younger patients (30,31). Peiris et al. (32) postulated that canal differentiation in the first and second molars is typically completed around ages 30-40, suggesting that MM canals may be more commonly detected in mandibular molars within this age range. Azim et al. (14) found a correlation between the presence of MM canals and age, noting a heightened prevalence in patients aged 30 to 40 years. Several other studies have similarly indicated a higher prevalence of the MM canal around age 30 and within the 30-40 age range (16,33). In research focused on the Indian demographic, a notable decline in MM canal prevalence was observed with advancing age (33). Another study indicated that in terms of MM canal prevalence, no associations were identified about patient age, gender, or mandible quadrants (34).

A major strength of our study lies in the utilization of CBCT for examination. We benefited from pre-existing patient images acquired for unrelated purposes. Additionally, we could ascertain both age and gender in a large sample of images. Nevertheless, our study had some limitations. The CBCT scans were sourced solely from the Department of Oral, Dental, and Maxillofacial Radiology of Dicle University, which underscores the potential benefit of incorporating data from diverse

radiology centers to gain a more comprehensive understanding of MM canal prevalence in the population.

Conclusions

Based on our findings, the MM canal is occasionally observed in mandibular molars, predominantly in the first molars. There was no significant association between the presence of the MM canal and the patient's age or gender. The majority of identified MM canals were of the confluent type.

Conflict of Interest

The authors disclaim any conflict of interest regarding this work.

References

1. Tashkandi N, Alghamdi F. Effect of Chemical Debridement and Irrigant Activation on Endodontic Treatment Outcomes: An Updated Overview. *Cureus* 2022;14(1):e21525.
2. Michetti J, Maret D, Mallet J-P, Diemer F. Validation of cone beam computed tomography as a tool to explore root canal anatomy. *J Endod* 2010;36(7):1187-1190.
3. Kim S-Y, Kim BS, Woo J, Kim Y. Morphology of mandibular first molars analyzed by cone-beam computed tomography in a Korean population: variations in the number of roots and canals. *J Endod* 2013;39(12):1516-1521.
4. Goel N, Gill K, Taneja J. Study of root canals configuration in mandibular first permanent molar. *J Ind Soci Pedod and Preven Dent* 1991;8(1):12-14.
5. Fabra-Campos H. Three canals in the mesial root of mandibular first permanent molars: a clinical study. *Int Endod J* 1989;22(1):39-43.
6. Çalışkan MK, Pehlivan Y, Sepetçioğlu F, Türkün M, Tuncer SŞ. Root canal morphology of human permanent teeth in a Turkish population. *J Endod* 1995;21(4):200-204.
7. Pomeranz HH, Eidelman DL, Goldberg MG. Treatment considerations of the middle mesial canal of mandibular first and second molars. *J Endod* 1981;7(12):565-568.
8. Nagendrababu V, Murray P, Ordinola-Zapata R, Peters O, Rôças I, Siqueira Jr J, et al. A protocol for developing reporting guidelines for laboratory studies in Endodontology. *Int Endod J* 2019;52(8):1090-1095.
9. Tahmasbi M, Jalali P, Nair MK, Barghan S, Nair UP. Prevalence of middle mesial canals and isthmi in the mesial root of mandibular molars: an in vivo cone-beam computed tomographic study. *J Endod* 2017;43(7):1080-1083.
10. Fu Y, Deng Q, Xie Z, Sun J, Song D, Gao Y, et al. Coronal root canal morphology of permanent two-rooted mandibular first molars with novel 3D measurements. *Int. Endod J* 2020;53(2):167-175.
11. Alhujhuj RR, Jouhar R, Ahmed MA, Almujhim AA, Albutayh MT, Adanır N. Evaluation of Root Canal Configuration of Maxillary and Mandibular First Molar by CBCT: A Retrospective Cross-Sectional Study. *Diagnostics* 2022;12(9):2121.
12. Yang L, Han J, Wang Q, Wang Z, Yu X, Du Y. Variations of root and canal morphology of mandibular second molars in Chinese individuals: a cone-beam computed tomography study. *BMC Oral Health* 2022;22(1):274-286.
13. Kuzekanani M, Haghani J, Nosrati H. Root and canal morphology of mandibular third molars in an Iranian population. *J Dent Res, Dental Clin, Dent Prosp* 2012;6(3):85-88.
14. Azim AA, Deutsch AS, Solomon CS. Prevalence of middle mesial canals in mandibular molars after guided troughing under high magnification: an in vivo investigation. *J Endod* 2015;41(2):164-168.
15. Zheng Q-H, Wang Y, Zhou X-D, Wang Q, Zheng G-N, Huang D-M. A cone-beam computed tomography study of maxillary first permanent molar root and canal morphology in a Chinese population. *J Endod* 2010;36(9):1480-1484.
16. Nosrat A, Deschenes RJ, Tordik PA, Hicks ML, Fouad AF. Middle mesial canals in mandibular molars: incidence and related factors. *J Endod* 2015;41(1):28-32.
17. Wang Y, Zheng Q-h, Zhou X-d, Tang L, Wang Q, Zheng G-n, et al. Evaluation of the root and canal morphology of mandibular first permanent molars in a western Chinese population by cone-beam computed tomography. *J Endod* 2010;36(11):1786-1789.
18. Pan JYY, Parolia A, Chuah SR, Bhatia S, Mutalik S, Pau A. Root canal morphology of permanent teeth in a Malaysian subpopulation using cone-beam computed tomography. *BMC Oral Health* 2019;19(1):1-15.

19. Marceliano-Alves MF, Lima CO, Bastos LGdPMN, Bruno AMV, Vidaurre F, Coutinho TM, et al. Mandibular mesial root canal morphology using micro-computed tomography in a Brazilian population. *Aust Endod J* 2019;45(1):51-56.
20. Versiani MA, Ordinola-Zapata R, Keleş A, Alcin H, Bramante CM, Pécora JD, et al. Middle mesial canals in mandibular first molars: a micro-CT study in different populations. *Arch Oral Bio* 2016;61:130-137.
21. Mannocci F, Peru M, Sherriff M, Cook R, Pitt Ford T. The isthmuses of the mesial root of mandibular molars: a micro-computed tomographic study. *Int Endod J* 2005;38(8):558-563.
22. Gu L, Wei X, Ling J, Huang X. A microcomputed tomographic study of canal isthmuses in the mesial root of mandibular first molars in a Chinese population. *J Endod* 2009;35(3):353-356.
23. Gulabivala K, Aung T, Alavi A, Ng YL. Root and canal morphology of Burmese mandibular molars. *Int Endod J* 2001;34(5):359-370.
24. Gulabivala K, Opananon A, Ng YL, Alavi A. Root and canal morphology of Thai mandibular molars. *Int Endod J* 2002;35(1):56-62.
25. de Carvalho MCC, Zuolo ML. Orifice locating with a microscope. *J Endod* 2000;26(9):532-534.
26. Vertucci FJ. Root canal anatomy of the human permanent teeth. *Oral Surg, Oral Med, Oral Pathol* 1984;58(5):589-599.
27. Sert S, Bayirli GS. Evaluation of the root canal configurations of the mandibular and maxillary permanent teeth by gender in the Turkish population. *J Endod* 2004;30(6):391-398.
28. Ahmed HA, Abu-Bakr N, Yahia N, Ibrahim Y. Root and canal morphology of permanent mandibular molars in a Sudanese population. *Int Endod J* 2007;40(10):766-771.
29. Xu S, Dao J, Liu Z, Zhang Z, Lu Y, Zeng X. Cone-beam computed tomography investigation of middle mesial canals and isthmuses in mandibular first molars in a Chinese population. *BMC Oral Health* 2020;20(1):135.
30. Rokaya ME, Kamel WH, Hassan KS. Middle Mesial Canals Prevalence percentage and Its Configuration type with "Egyptian subpopulation" by CBCT. *Oral Health Dental Sci* 2023;7(1):1-5.
31. Yang Y, Wu B, Zeng J, et al. Classification and morphology of middle mesial canals of mandibular first molars in a southern Chinese subpopulation: a cone-beam computed tomographic study. *BMC Oral Health* 2020;20(1):358.
32. Peiris H, Pitakotuwage T, Takahashi M, Sasaki K, Kanazawa E. Root canal morphology of mandibular permanent molars at different ages. *Int Endod J* 2008;41(10):828-835.
33. Sherwani OAK, Kumar A, Tewari RK, Mishra SK, Andrabi SMUN, Alam S. Frequency of middle mesial canals in mandibular first molars in North Indian population-An in vivo study. *Saudi Endod J* 2016;6(2):66-70.
34. Hatipoğlu FP, Mağat G, Hatipoğlu Ö, Nessrin Taha, Alfirjani S, Abidin IZ, et al. Assessment of the Prevalence of Middle Mesial Canal in Mandibular First Molar: A Multinational Cross-sectional Study with Meta-analysis. *J Endod* 2023;49(5):549-558.