

Comparison of Root Canal Filling Quality and Periapical Health Using Periapical, Panoramic, and Cone-beam Computed Tomography Radiographic Techniques

Maryam Janani¹, Negin Ghasemi¹, Masoumeh Johari², Leila Nazari³

¹ Department of Endodontics, Faculty of Dentistry, Tabriz University of Medical Sciences, Tabriz, Iran

² Department of Oral and Maxillofacial Radiology, Faculty of Dentistry, Tabriz University of Medical Sciences, Tabriz, Iran

³ Postgraduate Student of Endodontics, Faculty of Dentistry, Tabriz University of Medical Sciences, Tabriz, Iran

Received 16 June 2021 and Accepted 28 February 2022

Abstract

Introduction: Radiography is one of the techniques used to evaluate the quality of obturation. This study compared the quality of root canal obturation and periapical tissue using periapical and panoramic radiographs and cone-beam computed tomography (CBCT). **Methods:** This descriptive cross-sectional study was conducted on 138 teeth of patients referring to Tabriz Faculty of Dentistry, Tabriz University of Medical Sciences, Tabriz, Iran. The patients were in the 15-72 age range and had undergone CBCT, panoramic, and periapical x-ray examinations of their endodontically treated teeth. The patients' periapical, panoramic, and CBCT radiographs were retrieved from the faculty archives and studied. All the images and results were studied by an endodontist and a radiologist separately. **Results:** The results showed a significant difference between panoramic radiography and CBCT in identifying samples without voids. Panoramic radiographs showed the most samples without voids, and the CBCT method showed the least samples without voids (23.7% vs. 2.2%). The highest agreement in identifying the lesions was obtained between the panoramic and periapical methods. The CBCT technique showed the highest frequency (97.3%, $P=0.003$) of bone thickness changes in samples with lesions. **Conclusion:** Based on the results, a significant difference in the quality of root canal obturation was observed between periapical and panoramic radiographs with CBCT; however, no significant difference was observed between periapical and panoramic radiographs.

Keywords: Cone-beam Computed Tomography, Panoramic technique, Periapical radiography.

Janani M, Ghasemi N, Johari M, Nazari L. Comparison of Root Canal Filling Quality and Periapical Health Using Periapical, Panoramic, and Cone-beam Computed Tomography Radiographic Techniques. *J Dent Mater Tech.* 2022; 11(1): 37-46.

Introduction

Removal of infected pulp by mechanical and chemical cleaning and complete root canal obturation are important steps in endodontic treatment (1). Proper preparation and obturation, initial radiographs, and determination of the working length are factors that affect the prognosis of treated root canals (2). Usually the overall quality of the root canal obturation in teeth that have only single or two canals is better than molar teeth (3).

Coronal microleakage is due to insufficient sealing, which can be reduced using the minimum thickness of intra-orifice barrier materials, such as CEM (4).

Conventional intraoral radiographs are the most commonly used images for evaluating endodontic treatments (5). Periapical radiography is the only clinical method for evaluating endodontic treatments due to its less invasive nature (6). This radiograph can be used to examine the status of the pulp and pericardial tissues. The main limitation of periapical radiography is that it is two-dimensional; therefore, it is often necessary to take another horizontal or vertical radiograph to better determine root canal anatomy (7). The parameters

affecting periapical radiography, including the tube current, exposure time, and the film processing step, must be carefully controlled for the desired density and contrast (8).

Panoramic radiography is used to evaluate the general condition of the patient's mouth, including the presence of pathological lesions, bone density, TMJ status, and the condition of the teeth (9). The main advantages of this radiographic technique include extensive coverage of facial bones and teeth, a low radiation dose of the patient, patient comfort during radiography, and short radiography time (10). However, the main disadvantages of this radiographic technique include a lack of fine anatomic details and non-uniform image magnification (11, 12).

Cone-beam computed tomography (CBCT) was first used for angiography in 1982; however, it was later proposed for maxillofacial imaging (13, 14). Applications of the CBCT technique in endodontic treatments include determining tooth morphology, fractures, internal and external analysis of the root canal, identification of calcified canals, diagnosis of perforations, and evaluation of complications during and after root canal treatment (15, 16).

Scarf et al. reported the advantages and disadvantages of CBCT images in endodontic treatments. The advantages include displaying anatomical structures in three dimensions, data collection in three spatial planes, magnification, adjustment of the visual field, and accurate measurement without distortion (17). Regarding the disadvantages of CBCT images, one can refer to lower spatial resolution, higher sensitivity to movement, and lower accuracy in measuring bone density, compared to the CT scan technique (18, 19).

Huybrechts et al. examined the number of voids in root canal obturation materials using three analog, digital, and CBCT radiographic methods. The results showed the digital technique's superiority in detecting small voids through the analog and CBCT techniques. However, due to the two-dimensional nature of the digital technique, there might be errors in void detection (20).

Demir Alp et al. conducted a study on extracted mandibular molars in 2012 and evaluated the quality of obturation using conventional, digital, panoramic, and CBCT radiographic methods. The results showed the superiority of the CBCT technique over conventional and digital radiographic techniques (21).

It is impossible to carry out CBCT preparation for all the patients; therefore, periapical and panoramic radiographs are used more frequently in assessing the quality of

previous treatments and periapical status. Moreover, there is a paucity of studies on the diagnostic accuracy of panoramic, periapical, and CBCT imaging techniques. Therefore, this comparative study evaluated root canal obturation quality and periapical health using periapical, panoramic, and CBCT radiographic techniques.

Materials and Methods

The present descriptive cross-sectional study compared the quality of root canal obturation and periapical tissue health using periapical, panoramic, and CBCT radiographs. The study protocol was approved by the Ethics Committee of Tabriz University of Medical Sciences, Tabriz, Iran (IR.TBZMED.REC.1397.516). This study included subjects in the age range of 15-72 years, with endodontically treated teeth, who did not have any posts in the root canal space on periapical, panoramic, and CBCT radiographs after endodontic treatment. The subjects did not have any systemic diseases (e.g., diabetes) affecting the health and healing of periapical lesions. Periapical radiographs should be well-established and without elongation or foreshortening. In this study, 138 radiographs were examined from patients referring to the Tabriz Faculty of Dentistry, Tabriz University of Medical Sciences, Tabriz, Iran. The preparation time of radiographs was close to each other after endodontic treatments. Periapical, panoramic, and CBCT radiographs of the patients were retrieved from the faculty archives and studied. In total, 138 CBCT scans and several panoramic images (per patient) along with 138 periapical radiographs of endodontically treated teeth were collected.

A dental x-ray machine (PHILIPS, Holland, Amsterdam), film No. #2, and bisecting technique were used to prepare periapical radiographs. Panoramic images were prepared using a Ray Scan device (Samsung, Korea, Seoul). During the preparation of this type of radiography, any metal object, including earrings and hairpins, was removed from the patients' heads and necks, and CBCT images were taken using a powerful NewTom VGI scanner (Verona, Italy). High-resolution images were achieved with an exposure time of 12 sec, 80 kVp, and 8 mA. In this study, the radiographs were obtained from the archives of Tabriz Faculty of Dentistry, Tabriz, Iran. All the radiographs were available before the study and prepared by a radiology technician using one type of device and film. Due to the prevention of additional exposure and costs for patients, additional radiography was not prescribed, and all of the periapical radiographs were prepared using a bisecting angle technique. Cross-sectional, axial, and coronal planes were evaluated in CBCT radiography. This study examined the quality of obturation in terms of the

presence or absence of voids and their number and the health of periapical tissues in terms of the presence or absence of periapical lesions. Panoramic and CBCT radiographic examinations were performed by magnifying the scans in the software. Periapical radiography was conducted using a magnifying glass up to two times the original images. All the images and results were studied separately by an endodontist and a radiologist. Based on CBCT periapical index scores in the mentioned studies, grades 2 to 5 in this study were considered periapical lesions.

The data were analyzed using SPSS 20. Descriptive statistics were presented as mean±SD and frequency. Chi-squared test was utilized to compare the quality of obturation (presence or absence of void) as well as periapical health (presence or absence of lesion) in all the three tested methods of periapical, panoramic, and CBCT.

Results

In the periapical method, 17.3% of the samples did not exhibit voids, and 61.2% and 21.6% had 1-2 and 3-4 voids, respectively. In the panoramic method, 23.7% of the samples did not have voids, and 74.8% and 1.4% had 1-2 and 3-4 voids, respectively. In the CBCT method, 2.2% of the samples did not exhibit voids, and 51.8%, 35.3%, and 10.8% of samples had 1-2, 3-4, and 5-6 voids, respectively. There was no significant difference between periapical and panoramic radiographs in samples without voids and those with 1-2 voids ($P>0.05$); however, there was a significant difference between panoramic and CBCT radiographs with 3-4 voids and those without voids ($P<0.05$). The chi-squared test showed a significant difference in void rates between the three methods. The panoramic method showed that most samples had no voids, and the CBCT method showed the least number of samples without voids. The CBCT method also showed that 10.8% of the samples had 5-6 voids, which were not identified in the other two methods (Figure 1).

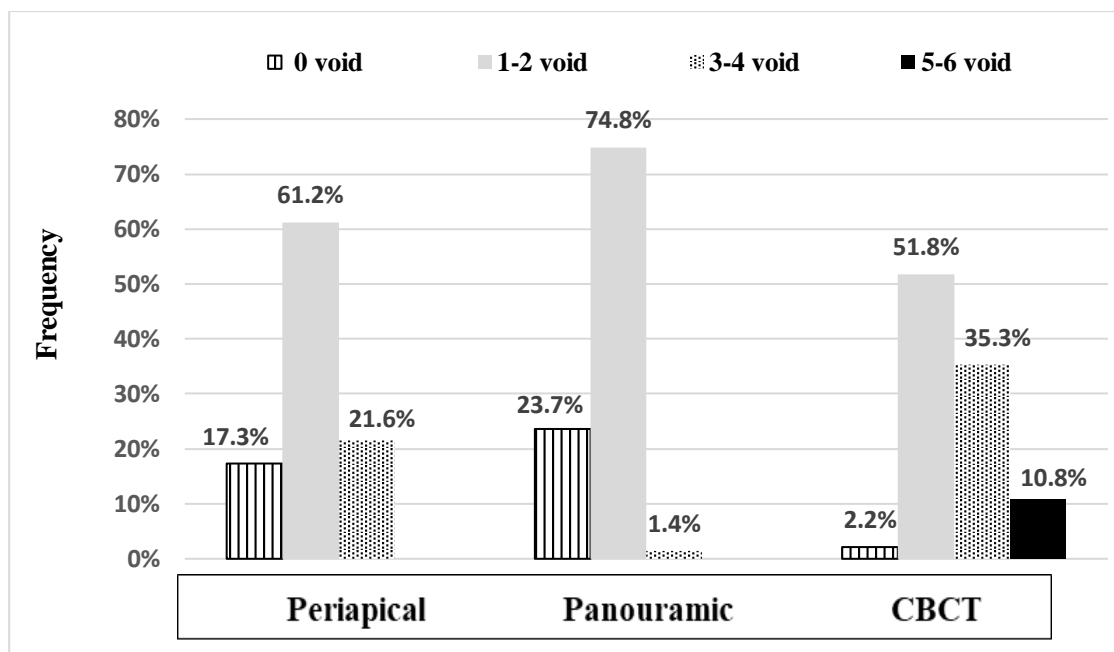


Figure 1. Comparison of void numbers between the three methods of periapical, panoramic, and CBCT radiography.

Regarding the frequency of lesions in the periapical method, 79% of the samples had no lesions, and 21% had lesions. The panoramic method showed that 79% of the samples did not have lesions, and 21% had lesions; however, in the CBCT method, 73.2% of the samples had no lesions, and 26.8% had lesions. Out of the 37 lesions identified by CBCT, 9 (24.3%) cases were not detected

by periapical radiography, and 9 (24.3%) cases were not detected by panoramic radiography (Figure 2). No

significant difference was found in the frequency of lesions between the three methods ($P>0.05$).

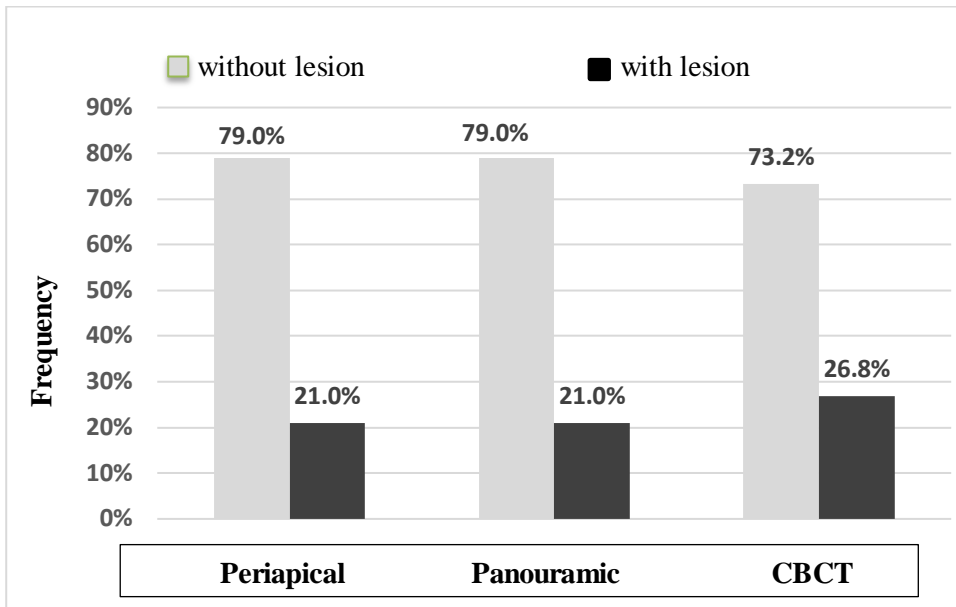


Figure 2. Comparison of lesion frequencies between the three methods of periapical, panoramic, and CBCT radiography.

Kappa's agreement in lesion identification was estimated at 0.956, 0.802, and 0.803 in the panoramic-periapical, panoramic-CBCT, and periapical-CBCT methods, respectively. The highest agreement in identifying lesions was observed between the panoramic and periapical methods.

Evaluation of the bone thickness changes in samples with lesions showed that in the CBCT method, 2.7% of the samples showed no bone changes, and 97.3% showed changes in the bone surface.

The examination of the relationship between cases with voids and the presence of lesions showed that in the periapical method, among cases with the lesion, 10.3% had no voids, and 37.9% and 51.7% had 1-2 and 3-4

voids, respectively. Among the samples with lesions in the panoramic method, 13.8% had no voids, and 82.8% and 3.4% had 1-2 and 3-4 voids, respectively. There was no significant difference between periapical and panoramic radiographs in samples without voids ($P > 0.05$); however, there was a significant difference between radiographs with 1-2 and 3-4 voids ($P < 0.05$). In the CBCT method, among the samples with lesions, 21.6%, 51.4%, and 27% had 1-2, 3-4, and 5-6 voids, respectively, and no case was observed without voids. There was a significant difference between CBCT and periapical radiographs in samples without void ($P < 0.05$). There was also a significant difference between CBCT and panoramic radiographs without voids and those with 1-2 and 3-4 voids ($P < 0.05$) (Table I).

Table I. Relationship between the presence of voids and lesions in the three radiography methods

Radiography techniques	Presence or absence of lesion	Number and percentage of voids	Void				Total number and percentage of voids
			0	1-2	3-4	5-6	
Periapical	No lesion	Number	21	74	15		110
		Percentage	13.8%	67.9%	18.3%		100%
	Lesion	Number	15	11	3		29
		Percentage	10.3%	37.9%	51.7%		100%
Panoramic	No lesion	Number	29	80	1		110
		Percentage	25.7%	73.4%	0.9%		100%
	Lesion	Number	4	24	1		29
		Percentage	13.8%	82.8%	3.4%		100%
CBCT	No lesion	Number	3	64	30	5	102
		Percentage	3.0%	62.4%	29.7%	5.0%	100%
	Lesion	Number		8	19	10	37
		Percentage		21.6%	51.4%	27.0%	100%

Among the samples with voids in the CBCT method, 36 samples had bone changes, with 22.2%, 52.8%, and 25%

of samples having 1-2, 3-4, and 5-6 voids, respectively (Table II).

Table II. Relationship between the presence of voids and bone densities in the CBCT method

Radiography techniques	Presence or absence of bone changes	Number and percentage of voids	Void				Total number and percentage of voids
			0	1-2	3-4	5-6	
CBCT	No bone changes	Number	3	64	30	6	103
		Percentage	2.9%	61.8%	29.4%	5.9%	100%
	Bone changes	Number		8	19	9	36
		Percentage		22.2%	52.8%	25.0%	100%

In this study, the periapical lesion was defined based on the CBCT periapical index scores; therefore, scores 2-5 were defined as periapical lesions (22) (Table III).

Table III. Cone-beam computed tomography periapical index scores

Score	Quantitative bone alterations in mineral structures
0	Intact periapical bone structures
1	Diameter of periapical radiolucency > 0.5-1 mm
2	Diameter of periapical radiolucency > 1-2 mm
3	Diameter of periapical radiolucency > 2-4 mm
4	Diameter of periapical radiolucency > 4-8 mm
5	Diameter of periapical radiolucency > 8 mm
Score (n) +E*	Expansion of periapical cortical bone
Score (n) +D*	Destruction of periapical cortical bone

Discussion

In the endodontically treated teeth, maximum effort should be made to remove microorganisms and obturate the entire length of the root canal to create a complete seal in the prepared canals and prevent treatment failure (1). The final obturation material is a combination of condensed gutta-percha cones and sealer, and their full adaptation with the canal walls is necessary for a proper seal (2).

In 2014, Saberi et al. showed that the warm vertical technique had a better sealing ability than the lateral condensation and thermoplasticized injectable gutta-percha techniques against bacterial leakage in teeth with oval-shaped canals (23).

Kositbowornchai et al. studied the amount of void space in root canal obturations using conventional and digital radiography and reported that both techniques were equal in detecting the amount of empty space (24).

Periapical, panoramic, and CBCT radiographs were used in this study. Cross-sectional, axial, and coronal plans have been evaluated in CBCT radiography (Figure 3-6). The comparison of the number of voids showed a significant difference in the quality of root canal obturation among the three methods. The panoramic and CBCT methods showed the highest and the least number of samples without voids, respectively. In the CBCT method, 10.8% of samples contained 5-6 voids; however, none of the samples had 5-6 voids, and there was no significant difference in samples without void and those with 1-2 voids in the periapical and panoramic methods.

In 2011, Liang et al. examined voids and periapical lesions using CBCT and periapical radiographic techniques. According to this study, CBCT identified more voids and periapical lesions than periapical radiographs (25).

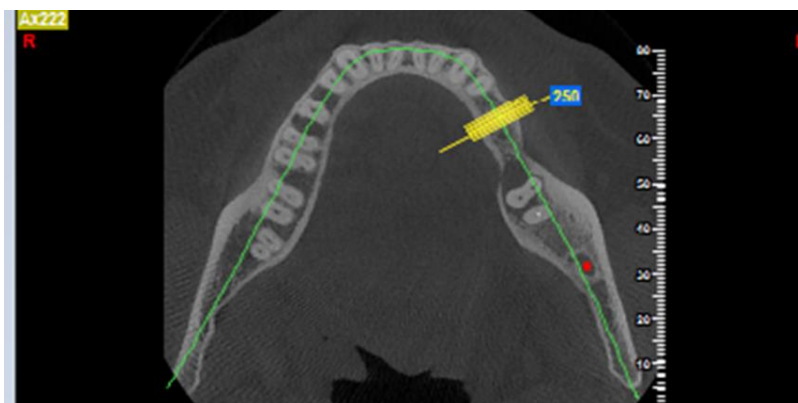


Figure 3. Axial CBCT image of tooth #20 with root canal treatment.

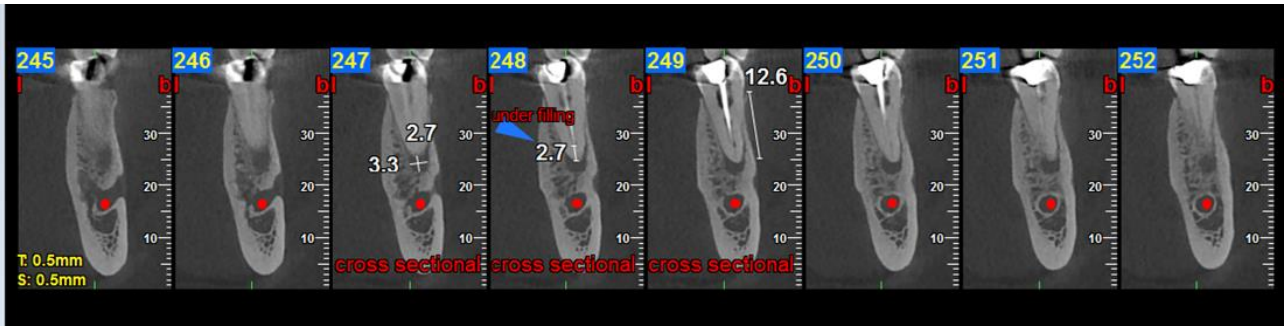


Figure 4. Cross-sectional CBCT image of tooth #20 with root canal treatment

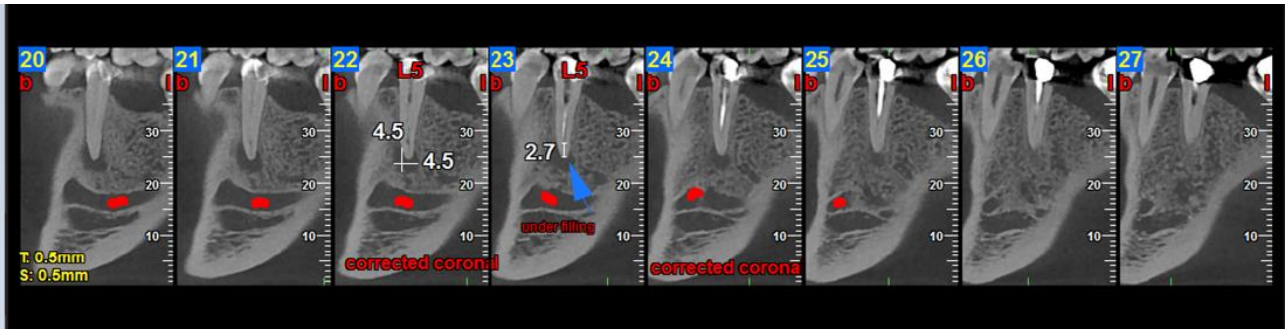


Figure 5. Corrected coronal CBCT image of tooth #20 with root canal treatment.

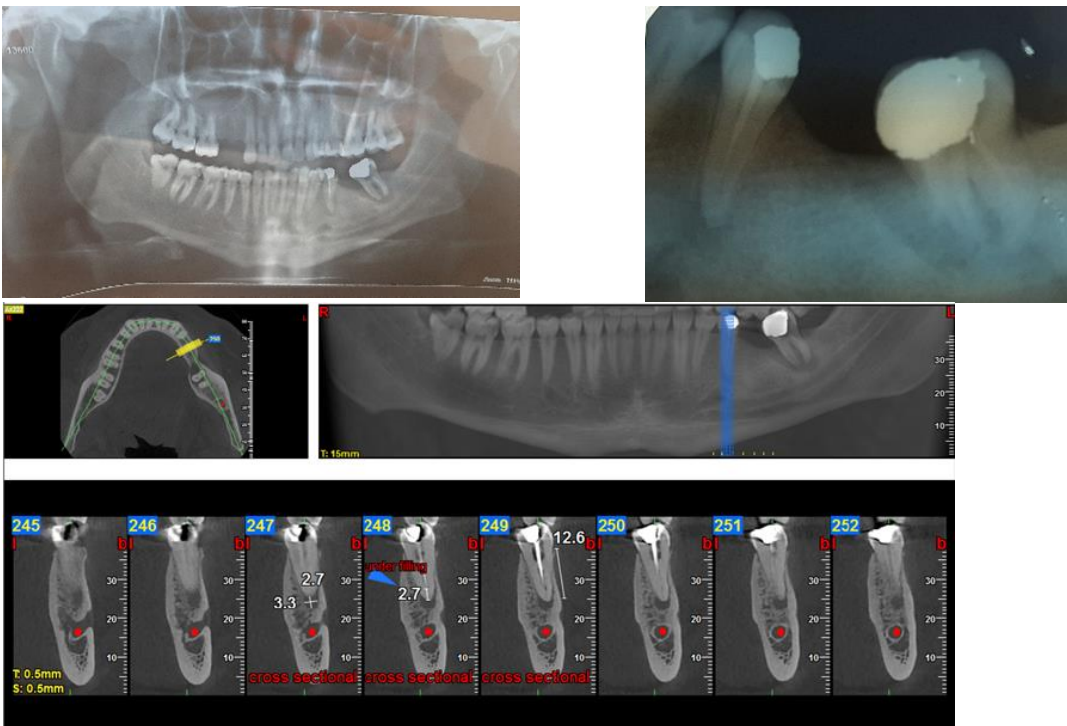


Figure 6. Comparison of panoramic, CBCT, and periapical radiography of tooth #20 with root canal treatment.

Huybrechts et al. showed no difference between digital imaging, analog radiography, and CBCT in detecting voids >300 µm; however, smaller voids were better detected by digital radiography than analog radiography and CBCT (20). In another study, Moller et al. showed significant differences in the diagnosis of small voids

between analog, digital, and CBCT intraoral radiographic imaging techniques(26).

The results of the studies mentioned above were all consistent with those of the present study. However, in this study, the size of voids was not considered an

identification factor in the radiographs, and their number is important.

Based on the results, three-dimensional CBCT imaging is a better technique for detecting voids than other two-dimensional analog and digital radiographic methods. The differences in the results of studies can be explained by differences in the applied radiation doses.

In the present study, no significant difference was observed in lesion identification between the three methods; therefore, each periapical and panoramic method identified 21%, and the CBCT method identified 26.8% of the samples with lesions. In addition, the kappa agreement in identification of the lesion was 0.956, 0.802, and 0.803 for the panoramic-periapical method, panoramic-CBCT, and periapical-CBCT techniques, respectively. The highest agreement was observed in identifying the lesions by the panoramic-periapical techniques.

In 2007, Farman et al. showed that the diagnosis rate of apical periodontitis was 71%, 84%, and 93% using periapical imaging, CBCT technique, and histology method, respectively (27). This study described the value of periapical radiography in diagnosing limited apical periodontitis and showed that lesions were more detected using the CBCT method than periapical radiography.

In the same line, Dalili et al. reported a higher frequency of lesion detection by CBCT than panoramic radiography, so that 15.9% and 4.2% of cases of periapical radiolucent lesions were identified by CBCT and digital panoramic techniques, respectively. Moreover, a low Kappa agreement of 0.374 was detected between the panoramic method and CBCT in their study (28), which was lower than that in the present study. It should be noted that although in the present study, the agreement of CBCT with panoramic and periapical methods was less than the agreement between panoramic and periapical techniques, this level of agreement was acceptable.

Cheng et al. showed a low agreement between periapical radiography and CBCT in 2011, and approximately 30.3% of the obturation lengths reported in periapical radiographs were inappropriate by CBCT (18). Tsai et al. (2012) reported that the diagnostic value of CBCT in lesions >1.4 mm in diameter was excellent; however, the diagnostic value of periapical radiographs was low in any lesion size (29).

Approximately 30-50% of bone must be resorbed to view a periapical lesion. On the other hand, such factors as morphological diversity of the apical region, bone density, beam angle, radiographic contrast, and the

periapical lesion position affect the distinguishing power of radiography (30).

In a study conducted by Estrela et al. (2008), the frequency of apical periodontal lesions in endodontically treated teeth was 17.6% on panoramic radiographs and 63.3% on CBCT radiographs, which was approximately one-third of the lesions detectable on panoramic radiographs (31). In the present study, lesions were detected at a higher rate through the CBCT than the panoramic technique due to the high rate of false-negative diagnosis in the conventional panoramic radiography; however, this difference was not significant.

Furthermore, the artifact caused by the metal post is effective in the root canal in the apical region and affect the diagnosis and examination of this region (32).

It is suggested that more prospective clinical studies in this field should be performed with more data, the same type of teeth, and different study tools to compare the accuracy of these three radiographic methods and consider the factors affecting the clinical stability of the data.

Conclusion

The present study evaluated the quality of root canal filling and periapical health by periapical, panoramic, and CBCT radiographic techniques. Based on the results, the highest and the lowest number of void-free samples were observed in the panoramic and the CBCT radiography, respectively. Fewer samples with lesions were observed using periapical and panoramic radiographs compared to the CBCT method; however, there was no significant difference between the three methods regarding the frequency of lesions. Examination of cortical bone thickness change in samples with lesions showed significant differences between CBCT, panoramic, and periapical radiography methods. Moreover, in examining the relationship between the presence of voids and bone changes in the CBCT method, the highest and lowest number of voids were 3-4 and 1-2 in samples with voids, respectively. Eventually, the panoramic-periapical method could better identify the lesions.

Conflict of interest

None declared.

Acknowledgment

The authors wish to thank Dr. Hadi Abioghli for providing language edit of manuscript.

References

1. Siqueira Jr JF. Aetiology of root canal treatment failure: why well-treated teeth can fail. *International endodontic journal*. 2001;34(1):1-10.
2. Er O, Sagsen B, Maden M, Cinar S, Kahraman Y. Radiographic technical quality of root fillings performed by dental students in Turkey. *International endodontic journal*. 2006;39(11):867-72.
3. Ehsani M, Abesi F, Ghasemi T. Technical Quality of Root Fillings Performed by Dental Students in Babol Dental School. *Journal of Dental Materials and Techniques*. 2014;3(2):66-70.
4. Sadeghi S, Tabari R, Hosseini S. The Effect of Thickness on Sealing Ability of Calcium Enriched Cement as a Coronal Seal Barrier. *Journal of Dental Materials and Techniques*. 2017;6(4):159-62.
5. Hommeez G, Coppens C, De Moor R. Periapical health related to the quality of coronal restorations and root fillings. *International Endodontic Journal*. 2002;35(8):680-9.
6. Zhu-yi F, Qing W, You-cheng Y. Application of angulated periapical radiography and cone beam computed tomography in detection of missing root canals. *Shanghai Journal of Stomatology*. 2014;23(3).
7. Glickman GN. Preparation for treatment. *Pathway of the Pulp St Louis: Mosby*. 2002:77-109.
8. Kiarudi AH, Eghbal MJ, Safi Y, Aghdasi MM, Fazlyab M. The applications of cone-beam computed tomography in endodontics: a review of literature. *Iranian endodontic journal*. 2015;10(1):16.
9. Kalinowski P, Różyło-Kalinowska I. Panoramic radiomorphometric parameters in Polish patients. *Folia morphologica*. 2011;70(3):168-74.
10. Widyaningrum R, Faisal A, Mitrayana M, Mudjosemedi M. Oral cancer imaging: the principles of interpretation on dental radiograph, CT, CBCT, MRI, and USG. *Majalah Kedokteran Gigi Indonesia*. 4(1):1-14.
11. Stuart C, White P, Michael J. *Oral Radiology: principles and interpretation: ELSEVIER INDIA*; 2014.
12. Hazan-Molina H, Molina-Hazan V, Schendel S, Aizenbud D. Reliability of panoramic radiographs for the assessment of mandibular elongation after distraction osteogenesis procedures. *Orthodontics & craniofacial research*. 2011;14(1):25-32.
13. De Vos W, Casselman J, Swennen G. Cone-beam computerized tomography (CBCT) imaging of the oral and maxillofacial region: a systematic review of the literature. *International journal of oral and maxillofacial surgery*. 2009;38(6):609-25.
14. Scarfe WC, Levin MD, Gane D, Farman AG. Use of cone beam computed tomography in endodontics. *International journal of dentistry*. 2009;2009.
15. Talaeipour A, Fadaei B. *Oral radiology textbook: Noordanesh Publications*; 2001.
16. Badole GP, Warhadpande M, Bahadure RN, Badole SG. Nonsurgical endodontic treatment of permanent maxillary incisors with immature apex and a large periapical lesion: a case report. *General dentistry*. 2015;63(1):58-60.
17. Langland OE, Langlais RP, Preece JW. *Principles of dental imaging: Lippincott Williams & Wilkins*; 2002.
18. Cheng L, Zhang R, Yu X, Tian Y, Wang H, Zheng G, et al. A comparative analysis of periapical radiography and cone-beam computerized tomography for the evaluation of endodontic obturation length. *Oral Surgery, Oral Medicine, Oral Pathology, Oral Radiology, and Endodontology*. 2011;112(3):383-9.
19. Seo DG, Gu Y, Yi YA, Lee SJ, Jeong JS, Lee Y, et al. A biometric study of C-shaped root canal systems in mandibular second molars using cone-beam computed tomography. *International endodontic journal*. 2012;45(9):807-14.
20. Huybrechts B, Bud M, Bergmans L, Lambrechts P, Jacobs R. Void detection in root fillings using intraoral analogue, intraoral digital and cone beam CT images. *International Endodontic Journal*. 2009;42(8):675-85.
21. Demiralp KÖ, Kamburoğlu K, Güngör K, Yüksel S, Demiralp G, Üçok Ö. Assessment of endodontically treated teeth by using different radiographic methods: an ex vivo comparison between CBCT and other radiographic techniques. *Imaging science in dentistry*. 2012;42(3):129-37.
22. Estrela C, Bueno MR, Azevedo BC, Azevedo JR, Pécora JD. A new periapical index based on cone beam computed tomography. *Journal of endodontics*. 2008;34(11):1325-31.
23. Saberi E-a, Shahraki S, Ebrahimipour S, Rashed Mohassel A, Akbari N, Rezaei M. Comparison of bacterial leakage between 3 different root canal

- obturation techniques in oval shaped canals. *Journal of Dental Materials and Techniques*. 2014;3(3):112-7.
24. Kositbowornchai S, Hanwachirapong D, Somsopon R, Pirmsinthavee S, Sooksuntisakoonchai N. Ex vivo comparison of digital images with conventional radiographs for detection of simulated voids in root canal filling material. *International endodontic journal*. 2006;39(4):287-92.
 25. Liang Y-H, Li G, Wesselink PR, Wu M-K. Endodontic outcome predictors identified with periapical radiographs and cone-beam computed tomography scans. *Journal of Endodontics*. 2011;37(3):326-31.
 26. Møller L, Wenzel A, Wegge-Larsen AM, Ding M, Væth M, Hirsch E, et al. Comparison of images from digital intraoral receptors and cone beam computed tomography scanning for detection of voids in root canal fillings: an in vitro study using micro-computed tomography as validation. *Oral surgery, oral medicine, oral pathology and oral radiology*. 2013;115(6):810-8.
 27. Radiology P. seminars on maxillofacial imaging and interpretation Allan G. Farman, ed Berlin: Springer. 2007.
 28. Dalili Z, Kazemnezhad E, Behboudi H, Nemati S. A Comparison between Digital Panoramic View and Cone-Beam Computed Tomography (CBCT) Images in Diagnosis of Apical Radiolucent Lesions. *Journal of Mashhad Dental School*. 2012;36(4):293-300.
 29. Tsai P, Torabinejad M, Rice D, Azevedo B. Accuracy of cone-beam computed tomography and periapical radiography in detecting small periapical lesions. *Journal of endodontics*. 2012;38(7):965-70.
 30. Molven O, Halse A, Fristad I. Long-term reliability and observer comparisons in the radiographic diagnosis of periapical disease. *International Endodontic Journal*. 2002;35(2):142-7.
 31. Estrela C, Bueno MR, Leles CR, Azevedo B, Azevedo JR. Accuracy of cone beam computed tomography and panoramic and periapical radiography for detection of apical periodontitis. *Journal of endodontics*. 2008;34(3):273-9.
 32. Saunders W, Saunders E, Sadiq J, Cruickshank E. Technical standard of root canal treatment in an adult Scottish sub-population. *British Dental Journal*. 1997;182(10):382-6.

Corresponding Author

Leila Nazari

Postgraduate Student of Endodontics, Faculty of Dentistry, Tabriz University of Medical Sciences, Tabriz, Iran

Tel: 04532531666

Email: nazarileilag@gmail.com