

## Compound Odontoma with an Unusual Appearance: Case Report

Mahdi Niknami<sup>1</sup>, Pooneh Mohseni<sup>2</sup>, Maysa Mallahi<sup>3</sup>

<sup>1</sup>Assistant Professor, Department of Oral and Maxillofacial Radiology, Faculty of Dentistry, Tehran University of Medical Sciences, Tehran, Iran

<sup>2</sup>Postgraduate Student, Department of Oral and Maxillofacial Radiology, Faculty of Dentistry, Tehran University of Medical Sciences, Tehran, Iran

<sup>3</sup>Postgraduate Student, Department of Oral and Maxillofacial Radiology, Faculty of Dentistry, Tehran University of Medical Sciences, Tehran, Iran

*Received 4 April 2016 and Accepted 3 May 2016*

### Abstract

The term odontoma is used to identify a tumor that is characterized by the production of mature enamel, dentin, cementum and pulp tissue and may interfere with the eruption of the associated tooth. The present report describes an odontoma in a 13-year-old boy, which is associated with an impacted tooth through a canal.

**Key words:** compound odontoma, mandible, odontogenic tumor, impacted tooth

-----  
Niknami M, Mohseni P, Mallahi M. Compound Odontoma with an Unusual Appearance: Case Report. *J Dent Mater Tech* 2016; 5(4): 213-15.

### Introduction

The term odontoma is circumscribed to benign lesion of odontogenic origin and the mix character composed of dental epithelial and mesenchymal cells. Because of its limited and slow growth and well-differentiated tooth tissue, this lesion is considered to be a hamartoma and not a true tumor. (1-3)

Odontomas are the most common odontogenic tumor. (4) According to the 2005 classification of WHO (World Health Organization) two types of odontomas are acknowledged (5): (a) compound odontomas that usually are unilocular lesions containing multiple miniature tooth-like structures known as denticles and (b) complex odontomas that consist of an irregular mass of hard and soft dental tissues. Compound odontoma are about twice as

common as the complex type. The compound variety forms equally between men and women, 60% of complex odontomas occur in women. In rare circumstances a compound odontoma may erupt into the oral cavity of a child. (4, 6)

Most odontomas occur in the second decay of life and many times are found during investigation of delayed eruption of adjacent teeth (4). Sometimes they are large enough to cause a swelling of the jaw (4).

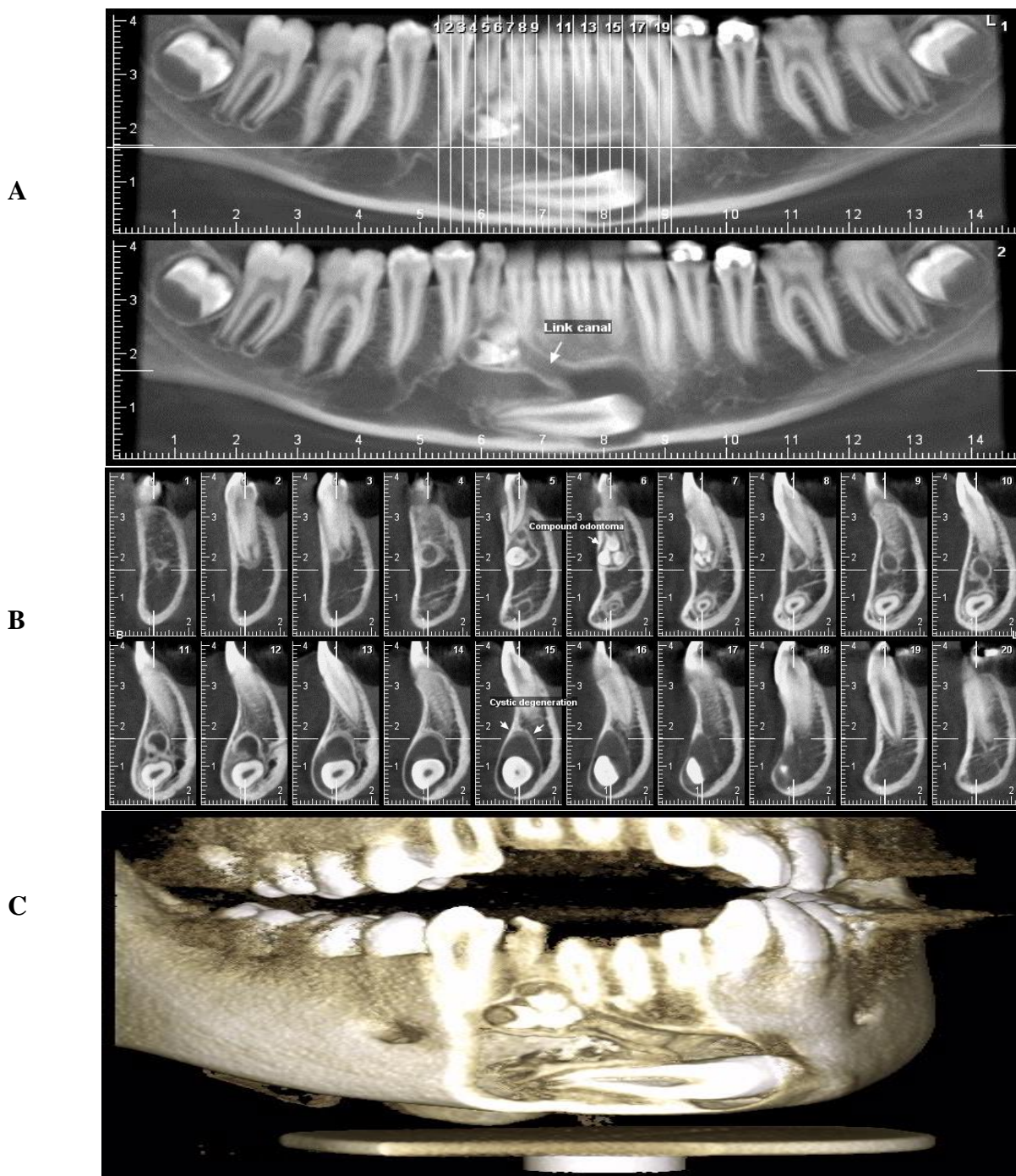
Surgical removal is the treatment of choice. Care should be taken, however, not to harm adjacent teeth and permanent germs in children, while follow-up is essential for evaluation of further development of the permanent dentition at the removal location. Although the diagnosis of odontomas, in most cases, can be provisionally confirmed by radiographic examination, a histological study of the removed lesion must be done to confirm the diagnosis(4).

### Case report

A 13-year-old boy attended our oral and maxillofacial radiology center with complaint of delay on eruption of permanent right mandibular canine. The clinical history did not reveal any systemic disorders. Intraoral examination revealed the absence of considered tooth. A panoramic radiograph was obtained which revealed the presence of horizontally impacted right mandibular canine with hyperplastic follicular space and multiple small radiopaque tooth-like structures in the apical region of retained right deciduous canine. The patient was asked to take a cone-beam computed tomography in order to assess the location and relationships of the lesion. The CBCT showed that impacted right mandibular canine lied in

The buccal side of apical region of anterior teeth and has a canalicular connection with small tooth-like structures (figure 1). The follicular space of impacted canine was hyperplastic. The tooth-like structures located in the apical region of deciduous canine and buccal side of permanent right lateral incisor. It was planned a surgical removal of the denticles with curettage of bone cavity and removing the impacted tooth. The size of the lesion did not require marsupialization before removal and the patient remained with a satisfactory amount of surrounding

bone. The removed contents were sent for histopathologic analysis. Macroscopic examination showed few small and calcified tooth like structures encapsulated by fibrous connective tissue. Histopathologic analysis showed the presence of tubular dentin adjacent to loose pulp connective tissue and an odontoblastic layer and pre-dentin at the periphery and also a squamous epithelial tissue with 2-4 layers surrounded by a capsule of fibrous connective tissue, confirming the existence of dentigerous cyst.



**Figure 1**-CBCT images showing compound odontoma that has canalicular connection with impacted canine.1-a.reconstructed panoramic, 1-b.crosssectional images, 1-c.3D image

## Discussion:

Many of case series have reported that the most of odontomas were diagnosed in the first two decades of life (7) which is in agreement with our case.

More of the compound types (62%) occur in the anterior maxilla in association with the crown of an unerupted canine (4), in this case we found the odontoma associated with the unerupted mandibular canine.

An impacted tooth is present in more than half of the cases (8).

There is significant controversy over gender distribution. In some studies odontomas are more common in females than in males (9) while in others these lesions found equally between both genders (10).

Most odontomas are associated with abnormalities such as impaction, malposition, diastema, aplasia, malformation and devitalization of adjacent teeth (4). In our case the compound odontoma connected by a canal to impacted cystic right mandibular canine which positioned horizontally.

Although tooth-like appearance of the radiopaque structures within a well-defined lesion leads to easy recognition of compound odontoma (4), Ameloblastic odontoma and ameloblastic fibroodontoma bear great resemblance to the common odontoma, particularly on a radiograph, and thus it is suggested that all Odontomas should be sent to an oral pathologist for microscopic examination and definitive diagnosis.(5)

## Acknowledgement

The authors would like to appreciate the head of oral and maxillofacial radiology department Dr. Mehrdad Panjnoush for his cooperation in preparation of CBCT images.

## Referencess

1. Baldawa RS, Khante KC, Kalburge JV, Kasat VO. Orthodontic management of an impacted maxillary incisor due to odontoma. *Contemp clin denti.* 2011; 2(1):37.

## Corresponding Author:

Pooneh Mohseni,  
Oral and Maxillofacial Department, Faculty of dentistry,  
North Kargar Street, Tehran, Iran  
E-mail: p.mohsenik@yahoo.com  
Tel: +98 9124431017

2. Yadav M, Godge P, Meghana SM, Kulkarni SR. Compound odontoma. *Contemp clin dent.* 2012; 3(5):13.
3. Cawson RA, Binnie WH, Speight PM, Barrett AW, Wright JM. *Lucas's pathology of tumors of the oral tissues.* Churchill livingstone; 1998:p.83-5
4. White SC,Pharoah MJ.Oral radiology:principles and interpretation.7<sup>th</sup> Ed. St.Louise: Mosby Co.2014:370-4
5. Morgan PR. Odontogenic tumors: a review. *Periodontology 2000.* 2011; 57:160-76.
6. Salgado H, Mesquita P. Compound odontoma— case report. *Revista Portuguesa de Estomatologia, Medicina Dentária e Cirurgia Maxilofacial.* 2013; 54(3):161-5.
7. Nelson BL, Thompson LD. Compound odontoma. *Head and neck pathol.* 2010 Dec; 4(4):290-1.
8. An SY, an CH, Choi KS. Odontoma: a retrospective study of 73 cases. *Imaging sci in dent.* 2012 Jun; 42(2):77-81.
9. Hisatomi M, Asaumi JI, Konouchi H, Honda Y, Wakasa T, Kishi K. A case of complex odontoma associated with an impacted lower deciduous second molar and analysis of the 107 odontomas. *Oral dis.* 2002; 8(2):100-5.
10. Serra Serra G, Berini Aytés L, Gay Escoda C. Erupted odontomas: a report of three cases and review of the literature. *Med Oral Patol Oral Cir Bucal,* 2009; 14, (6):299-303.