

A Review of Biopsy in Dentistry: Principles, Techniques, and Considerations

Massoumeh Zargaran

Department of Oral and Maxillofacial Pathology, Dental Research Center, Faculty of Dentistry, Hamadan University of Medical Sciences, Hamadan, Iran

Received 22 September 2013 and Accepted 2 January 2014

Abstract

Biopsy is a useful technique for definitive diagnosis of abnormal oral conditions and it must be performed carefully since any error may result in histopathologic misidentification of the lesion. Present study evaluated the most relevant literatures published between 1982 and 2012 in order to review existed guidelines of correct biopsy performance using scientific database sources such as PubMed, MEDLINE, IMEMR, and Chemical Abstract. The aim of this study was to increase knowledge of dental practitioners especially general dentists about factors which may influence optimization of oral biopsy.

Key words: Biopsy, dentistry, histopathology, oral lesion, specimen.

Introduction

Any lesion appearing in oral cavity should be carefully evaluated (1) while clinical diagnosis must be confirmed throughout different procedures (2).

In this context, microscopic analysis is accepted as a gold standard procedure to diagnose most of lesions (3), so the exact identification of their nature would be feasible only via histopathologic evaluation of tissue specimens taken from the patient by a biopsy technique (1,4). In addition, early diagnosis of some oral lesions, especially various malignancies, is only possible by taking biopsy specimens, which are important to improve patient prognosis (1). Nowadays, oral cancer is considered as a major health problem with increasing incidence and mortality rates in various parts of the world. Rapid and early diagnosis of oral cancer makes it possible to apply various conservative treatment modalities and shorter period of care with more favorable prognosis (5). Therefore, a delay in diagnosis or referral might have a great effect on mortality and morbidity associated with oral cancer (6). Dental practitioners have an important role in this context (7). The majority of researchers believe that proper knowledge, ability and sufficient expertise in relation to the recognition of symptoms and signs of malignant and premalignant lesions in clinical examinations, carrying out a biopsy procedure and its submission for histopathologic evaluation are associated with early diagnosis (7,8). In fact, more and widespread use of biopsies by dental practitioners will most probably decrease the number of legal actions due to belated diagnosis or lack of diagnosis of a lesion (9). The application of biopsies may also provide the correct diagnosis of oral lesions and some systemic diseases which decreases patients' problems and improve professional credibility of dentists (4).

Considering the importance of obtaining a biopsy all the dental practitioners, including general dental

Zargaran M. A Review of Biopsy in Dentistry: Principles, Techniques, and Considerations. J Dent Mater Tech 2014; 3(2): 47-54.

practitioners, should be able to take biopsies (2). However, it is not very common for dental practitioners to take biopsies due to lack of sufficient knowledge and awareness (1). Knowledge about the nature of a lesion is only one step in the pathway toward a correct diagnosis and proper management of the patient. Other steps of this pathway include the selection of the type of biopsy, correct implementation of the biopsy technique, proper fixation of the specimen obtained, transport and submission to the laboratory (10,11) and transfer of adequate and complete clinical information to the pathologist by general dental practitioners, which are all necessary to achieve the best results (11,12).

The principal aim of obtaining a biopsy is to provide a specimen for histopathologic diagnosis of lesions (12). Any error during biopsy procedure may lead to misidentification of the lesions by pathologists (4). Hence, the procedure should be carried out carefully and correctly in order to provide an appropriate specimen for pathological analysis (12). Regarding to the importance of awareness and knowledge of dental practitioners especially general dentists on biopsies issue (4); the aim of this study was to review indications and contraindications of biopsies, correct sampling techniques, and correct stage, transfer and submission techniques of biopsy specimens to the laboratory in order to prevent any errors in the diagnosis of lesions because arriving at a correct histopathologic interpretation depends on correct and precise implementation of treatment procedures, promoting health and survival of patients.

Definition

The process of obtaining a biopsy specimen from the oral mucosa is a simple surgical technique and general dental practitioners are able to take biopsies from some oral cavity lesions in order to establish a diagnosis (12,13). Biopsy specimens are usually taken before initiating the treatment procedures as the most accurate technique to reach a definitive diagnosis. The term "biopsy" is a combination of two Greek words of "bios" meaning "life" and "opsis" meaning "vision". Technically, biopsy is defined as taking a tissue specimen from a living organism in order to evaluate it under a microscope, with a diagnostic purpose. By using this technique, the histologic characteristics of the lesion are determined, it is differentiated from other lesions and its extent is recognized, based on which a treatment plan can be prepared. The results of biopsy can help to determine course of the disease, prediction of recovery, recurrence or progression of lesions. In addition, the results of biopsy procedures are invaluable in forensic medicine as hard evidence (1,9).

Biopsies Permissible for General Dental Practitioners

Obtaining biopsies in general dental office has several advantages for patients. Considering the rapport between the patient and the dentist, the patient will have a better feeling. In addition, the patient will cut down on the number of commutes and will spend less time waiting for the biopsy to be taken and for receiving its report. On the other hand, fewer patients will be referred to specially centers (14).

Based on suggestions made by Oliver, biopsies permissible for general dentists have been listed. Fibroepithelial polyp, pyogenic granuloma and epulis are lesions which can undergo biopsy techniques by general dental practitioners. In relation to mucocoeles, if care is exercised, they can be biopsied. Highly experienced dentists can biopsy mucosal lichen planus. However, general dental practitioners should refrain from taking biopsies from chronic ulcers, squamous cell carcinomas and small and large salivary gland tumors and should immediately refer the patient to a hospital. Patients with leukoplakia, erythroplakia, blistering lesions, such as pemphigus, and granulomatous diseases, too, should be referred to a hospital (15).

After a decision is made to obtain a biopsy specimen, the dentist should have the necessary skills and expertise and the necessary instruments. In addition, the dentist should be experienced in establishing a rapport with the patient, which is especially important when the dentist is to inform the patient of a malignant lesion (14).

Indications for Biopsy

Biopsies are not confined to the diagnosis of malignant tumors; they are widely used to determine the nature of various lesions (2). Biopsies should be obtained from the three following:

- Lip and oral lesions those do not originate from local irritative factors such as trauma or inflammation.
- Lesions which persist for more than 2 week after the exclusion of local irritants.
- Lesions suspected of malignancies (16).

Generally, oral lesions should be evaluated in relation to their rapport with local irritating factors, which should be eliminated after they are identified, and the patient should be followed for 15-20 days. If the lesions persist after this period of time, biopsies and histopathologic evaluations are necessary (1).

Osseous lesions with malignant features on X-rays should be evaluated from histopathologic point of view. It is necessary to histopathologically evaluate all the maxillary cysts, especially keratocysts. All the osseous lesions associated with pain, paresthesia and other signs and symptoms and rapidly expanding osseous lesions should undergo a biopsy procedure. Biopsies are indicated for all the oral mucosal lesions which have undergone significant and persistent color changes (very white, red or pigmented) or changes in the appearance,

such as ulcerations or proliferation, and there is a deep palpable hard mass (1). Biopsies are necessary to evaluate precancerous mucosal lesions and lesions such as lichen planus and leukoplakia in areas showing atrophy and erosion (16). Identification of some systemic conditions, such as lupus, amyloidosis, scleroderma and Sjögren syndrome, is possible by obtaining biopsy specimens from the oral tissues for definitive diagnosis. It is possible to diagnose Sjögren syndrome by taking biopsy specimens from the minor salivary glands on the lips. In addition, biopsies are useful to confirm some oral lesions resulting from certain infections such as syphilitic lesions and tuberculosis. Other uses of biopsies include diagnosis of blister lesions in mucocutaneous conditions with the involvement of oral mucosa, such as pemphigus vulgaris and cicatricial pemphigoid (1).

Contraindications of Biopsy

Biopsy is contraindicated in patients with severe medical conditions and in individuals with systemic disorders where a biopsy procedure will deteriorate the patient's medical status or will lead to complications (16). In cases in which the lesion is situated in very deep locations or in an area with difficult access, in which taking a biopsy will result in complications or injury to adjacent structures, biopsy should be avoided and the patient should be referred to a surgeon. Hemangioma is considered a contraindication for biopsy due to the risk of massive and persistent hemorrhage (17).

In patients receiving intravenous bisphosphonates if possible biopsy should be avoided (18) because they are at risk of bisphosphonate-related osteonecrosis of the jaw (BRONJ) (19,20). The BRONJ phenomenon is a serious condition triggered by trauma following invasive dental procedures (19,21). Biopsies are not recommended in multiple neurofibromas due to the risk of transformation to neurosarcoma and in major salivary gland tumors. In such cases biopsies should be obtained by a specialized surgeon in order to prevent traumas to adjacent anatomic structures or spread of tumor cells, which compromise patient prognosis. Biopsies are not necessary in lesions with known etiologies, i.e. trauma or inflammation, or normal anatomic variations, such as physiologic pigmentation of the gingiva, geographic tongue, linea alba, extostoses and tongue indentation (1).

Different Types of Biopsy

Biopsies are classified based on lesion characteristics, the technique and the materials used, duration and location of the lesion, preparation of the lesion and the aim of the biopsy procedure.

*Lesion characteristics: Biopsies are classified into two types based on lesion characteristics (1):

1. Direct: for superficial lesions with easy access

2. Indirect: for deep lesions located under normal tissues

*Biopsy technique: based on the technique deployed, biopsies are classified into two groups:

– *Incisional*: In this biopsy technique a part of the tissue representing the lesion is taken along with a part of the healthy tissue (22). Incisional biopsy is used when it is not possible to remove the whole lesion, such as lichen planus or a diffuse white patch. In addition, in cases in which the clinical diagnosis is unknown, the incisional biopsy is the technique of choice. In this technique, biopsies should be taken with an adequate depth (at least 3-4 mm in depth) to include the basement membrane and the underlying connective tissue. The length of the sample depends on the location of sampling. However, as a general suggestion, the length of the specimen is usually three times its width. The specimen should include some healthy tissue too, so that it can be used as a criterion for comparison with the lesion (14). If the lesion is extensive, multiple biopsies are taken, which are placed in separate containers. When these samples are submitted to the laboratory for histopathologic evaluation an outline image of the lesion is drawn as the location of each sample is marked on the image (23). In addition, several specimens are taken in cases in which it is difficult to remove the whole lesion due to its large size or complex position. Furthermore, this technique is useful in the diagnosis of systemic conditions (1). Incisional biopsy is used for lesions suspected of malignancy or in precancerous lesions. It is also used for chronic ulcers, squamous cell carcinoma, leukoplakia, erythroplakia, lichen planus and bullous lesions (14). There is controversy over the use of incisional biopsy in malignant lesions because some researchers believe that this procedure might lead to the invasion of malignant cells via bloodstream in the surgical wound created in the lesion site, increasing the risk of metastasis (24).

–*Excisional*: Excisional biopsy refers to the complete removal of a lesion or a suspected area (22) which contains diagnostic and therapeutic aims as well (1). In this technique the lesion is completely removed along with a margin of surrounding normal tissue and deep healthy tissue to ensure safety (25). This technique is used for small lesions (with a diameter of less than 1 cm), which are probably benign. The majority of biopsies in the general dental field are excisional. The technique is used for small benign lesions, including fibroepithelial polyps, papilomas, fibromas, mucoceles, hyperplastic tissues and pyogenic granulomas (14). In biopsies of some tumors such as hemangiomas and melanomas the lesion should be completely and extensively excised to prevent severe hemorrhage and metastatic spread of the tumor (23).

*Biopsy instruments: A number of cutting instruments, including scalpel blades, punches and B forceps, are used to take biopsies. Taking a biopsy from the oral mucosa with a punch is a rapid, easy, safe and cheap technique and can be used in the majority of oral cavity areas. Cylindrical samples measuring 2-8 mm in diameter can be obtained using this instrument. Small wounds created by a punch do not require suture whereas big wounds do (1). A punch can be used to take several biopsies from different locations in one session; it inflicts less stress and anxiety on the patient compared to a scalpel blade (26). It should be pointed out that taking biopsies with a punch is confined to superficial epidermal and mesenchymal lesions and has no application for taking biopsies from deep lesions. In addition, it is not advisable to use it in areas with rich vascular or nervous plexuses. It is difficult to take biopsies from the soft palate, maxillary tuberosity and the oral cavity floor with a punch due to the mobility of these areas (27). The majority of oral pathologists believe that incision with a scalpel blade results in less injuries (28). In addition, lasers and electrocautery should not be used to take biopsies (29) because they produce histologic artifacts due to the heat produced during the use of these instruments (30,31).

The Time to Take Biopsies

The samples can be taken and processed during surgery by freezing (intraoperative biopsy) or in a separate session by fixation (extraoperative biopsy). An intraoperative biopsy makes it possible to reach a rapid histopathologic diagnosis but the obtained sections have a no ideal quality with troublesome microscopic evaluation (1). The pathologist can only report a positive, negative or suspected result. However, it has the advantage of a report in a short time by the pathologist, which can be sent to the operating room. Therefore, the surgeon can make the necessary decision. This technique is used in cases which are suspected of malignancy but it is not always reliable and the surgical operation should be postponed, when there is doubt, until the definitive diagnosis is provided using evaluation of the samples processed through extra-operative technique. An important use of intra-operative biopsy is the margins of malignant tumors assessment during surgery so more extensive incisions can be made if the lesion is extra-widespread (1).

Sampling and processing in a separate session is a time-consuming method. However, this technique yields sections with a higher quality and easier histopathologic evaluations compared to intraoperative biopsy (1).

Location of Biopsy

Based on the area involved, specimens can be taken from different oral cavity locations, including salivary glands, lymph nodes and other head and neck tissues. It is easy to obtain a biopsy specimen from the oral cavity

mucosal tissues and generally it is used for differential diagnosis, evaluation of treatment outcomes or the lesion progression follow up (1).

Processing of Biopsy Specimens

Depending on the type of preparation specimens might be frozen or placed in paraffin or methacrylate. The specimens can also be evaluated without preparation in a fresh manner. Freeze specimens are frozen by dry ice and processed without fixation. Freezing at -40 to -60°C makes the tissue specimen firm and it can be cut using a microtome. Placement of the specimens in paraffin is the most commonly used technique (1) whereas the sample is fixed in 10% neutral buffered formalin (22), processed and embedded in paraffin. Finally, thin sections are cut, stained and evaluated under a light microscope (1).

Hard tissue specimens are placed in methacrylate and evaluated by an electron microscope, which helps differentiate normal cells from tumor cells based on morphologic characteristics (1). In evaluating fresh samples, the tissue specimen is immediately transferred to the laboratory and evaluated by immunofluorescence techniques. The specimens are moistened with saline solution and are prevented from drying. The specimens should be kept at 2-8°C and care should be taken to keep them from freezing during the interval from being taken to being transferred to the laboratory (1). Evaluation of fresh specimens by immunofluorescence is useful for diagnosing mucocutaneous conditions with an autoimmune origin such as pemphigus, pemphigoid, erythema multiform and lichen planus (1).

The Aim of Taking Biopsies

Biopsies are taken for diagnostic, therapeutic or research purposes. Research biopsies are usually taken to study new medical conditions and are carried out on laboratory animals and in some rare cases on man (1).

General Principles of Biopsies

There are some similar general principles for biopsies regardless of the type of biopsy (14). It has been recommended that before taking any biopsies written consent be taken from all the patients, with the reason for prescribing a biopsy procedure and details of possible risks being mentioned in the consent form. The risks are mainly related to the location of surgery. For example, paresthesia may occur in the tongue and lips (15). The biopsy should be obtained from the most prominent part of the lesion and in cases in which the lesion has different clinical views in different areas, several biopsies should be taken. Necrotic tissues and lacerated tissues should not be biopsied because such specimens yield little diagnostic data (14). The instruments needed for biopsy are usually the same as those used in surgery, including mirrors, various forceps, surgical blades, syringes for anesthesia etc (Fig. 1). (1). Similar to any other surgical procedure, it is

absolutely necessary to observe the principles of disinfection for instruments and the biopsy location and sterile gauze pieces and gloves should be used. After making sure that all the instruments needed are ready and available, an anesthetic agent is administered for anesthesia. Anesthetic agents containing vasoconstrictors are used to decrease hemorrhage. Injections should be made at a distance of 3-4 mm from the area under question (1) in order to prevent damage to the specimens (14). It is advisable to use elliptical incisions in order to take tissue specimens (15). Wounds created by such incisions, which have been properly designed, are easily sutured and closed (32). In addition, care should be exercised to place incisions away from blood vessels and major nerves as far as possible and it is better to place them parallel to blood vessels and nerves to minimize possible injuries (15). During removal of a tissue sample, it can be stabilized by a suture or forceps, if necessary (15). Of course, care should be taken not to tear or compress the biopsy specimen (1). If several tissue specimens are produced during sampling, all the segments should be sent to the laboratory. No selections should be made in order to send only the selected segments to the laboratory for histopathologic evaluation (22).

The biopsy specimen should immediately be placed in a fixating solution (14,22) because tissue autolysis takes place rapidly after resection and taking the specimen due to the disruption of blood supply to the tissue specimen (29). The best and most commonly used fixative is 10% neutral buffered formalin (22). Other solutions such as water, saline solution and alcohol are not suitable alternatives for formalin, as they cause severe and destructive changes in epithelial structures etc (Fig. 2) (33).

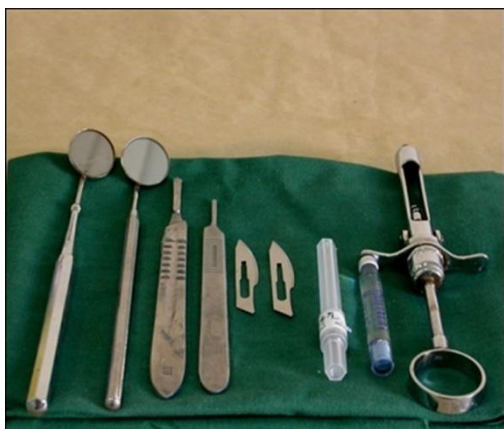

Figure 1. Some of instruments needed for biopsy

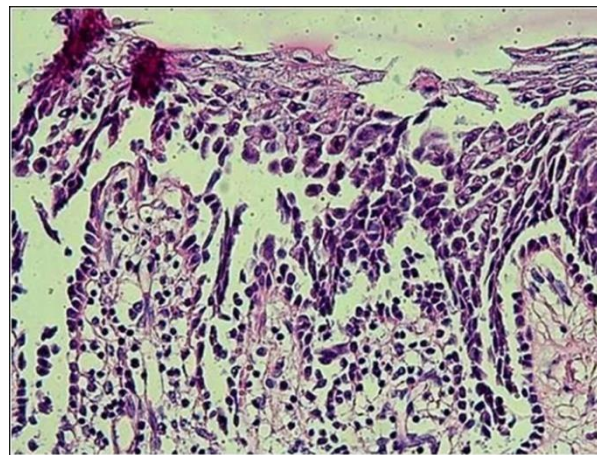


Figure 2. Artificial suprabasal cleft and acantholytic epithelial cells which mimic pemphigus (sample fixed in saline solution)

The biopsy specimen should be placed in a sufficient amount of the fixating agent; at least 10 times of tissue specimen's volume (14,15,22). Each biopsy specimen should be sent in a separate container and if more than one specimen is placed in one container, each one should be clearly marked (for example by using a suture) (Fig. 3). Explaining and describing the shape of each specimen is not a reliable technique because the shape of the specimen will probably change after fixing (15). The container which the specimen is placed in should have a wide opening. The specimen becomes hard and rigid after being fixed; therefore, it might be difficult to retrieve it from a container with a narrow opening (34), resulting in damage to the specimen (29). Plastic containers with screw caps are recommended for the transfer of biopsy specimens (29). Glass containers may break and injure operators. In addition, glass fragments might penetrate into the tissue specimen and damage the microtome during preparation of tissue sections. (Fig. 4) (34). Data such as the first name and family name of the patient (15), the clinician's name and the area which underwent the biopsy procedure should be written on a label on the container (15,29). The laboratory might not accept specimens which do not have any labels and return them to the clinician for solving the problem (34).

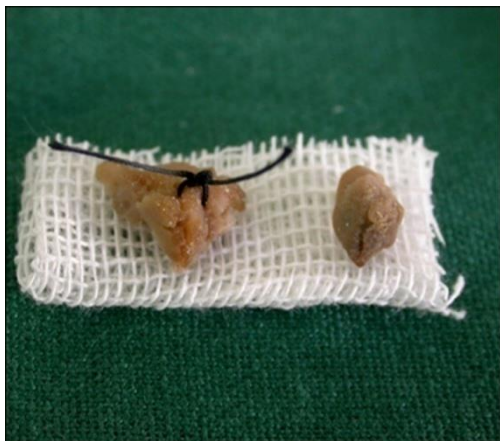

Figure 3. Samples of tongue (left – labeled with suture) and buccal mucosa (right)



Figure 4. Appropriate (left) and inappropriate (right) biopsy containers

Data Sent to the Pathologist

The biopsy specimen should be accompanied with a complete patient history and particulars (name, age, gender and medical history including the drugs used, use of alcohol and smoking), data in relation to the lesion (clinical appearance, presence of other lesions, the results of other evaluations, the type of the biopsy, clinical diagnoses) and also the name and address of the dentist in charge. It is very useful to include a diagram on the oral pathology biopsy requisition form to show the location and size of the specimen and area of sampling. Other details, including the shape and color of the lesion, its texture and radiographs (if any) should also be provided (14). Providing such data will contribute to a more thorough and comprehensive interpretation of the specimen (15). For example, some conditions are associated with age, gender and occupation (28). Providing clinical differential diagnosis is very valuable for pathologists because it contains the dentist's viewpoint about the lesion (9). Lack of clinical data or incorrect differential diagnoses will result in ordering unnecessary tests or use of a wide range of

immunohistochemical staining techniques (34). The evaluation of lesion radiographic images is usually useful for correct and proper classification of the disease and its diagnosis (9).

Complications of Oral Cavity Biopsies

In the most cases the incidence of complications are minimized by applying meticulous surgical techniques, although hemorrhage is possible to occur during the first 24 hours after sampling due to clot disruption or secondary to loosening of the suture. An uncommon problem in biopsies is wound dehiscence, which usually occurs 5-8 days after sampling; such a complication is attributed to infection or tight sutures, the latter of which leads to local obstruction of blood vessels. Another complication is paresthesia which might persist for several hours or months (1,25).

The majority of patients do not have severe pain after a biopsy procedure and in cases in which pain relief is necessary; analgesics bring about proper pain relief as the majority of patients experience pain relief after 3 days. The patients who have gone through biopsy procedure need to follow standard postoperative oral surgery instructions (15).

Conclusion

Considering the importance of biopsy for definitive diagnosis and management of oral lesions, dentists should be able to take biopsies while they must be aware of variety of factors influencing histopathologic interpretation of an oral biopsy specimen to prevent misidentification of the lesions. This review article is to increase knowledge of dental practitioners about principles, techniques and considerations of biopsy.

References

1. Mota-Ramírez A, Silvestre FJ, Simó JM. Oral biopsy in dental practice. *Med Oral Patol Oral Cir Bucal* 2007;12:504-10.
2. López-Jornet P, Velandrino-Nicolás A, Martínez-Beneyto Y, Fernández-Soria M. Attitude towards oral biopsy among general dentists in Murcia. *Med Oral Patol Oral Cir Bucal* 2007;12:116-21.
3. Kumaraswamy KL, Vidhya M, Rao PK, Mukunda A. Oral biopsy: Oral pathologist's perspective. *J Cancer Res Ther* 2012;8:192-8.
4. Zargaran M, Baghaei F, Musivand R. A Comparative Evaluation of Senior Students of Dentistry and Dental Medical Doctors' Knowledge

- on Harvesting and Handling of Oral Biopsies. *J Dent Shiraz Univ Med Scien* 2011;12:149-55.
5. Kujan O, Duxbury AJ, Glenny AM, Thakker NS, Sloan P. Opinions and attitudes of the UK's GDPs and specialists in oral surgery, oral medicine and surgical dentistry on oral cancer screening. *Oral Diseases* 2006;12:194-9.
 6. Lachlan M, Graham RO. Oral cancer awareness of undergraduate medical and dental students. *BMC Medical Education* 2007;7:1-31.
 7. Patton LL, Elter JR, Southerland JH, Ronald P, Strausst RP. Knowledge of oral cancer risk factors and diagnostic concepts among North Carolina dentists Implications for diagnosis and referral. *J Am Dent Assoc* 2005;136:602-10.
 8. Omolara G, Fashina AA. Oral Cancer Education in Dental Schools: Knowledge and Experience of Nigerian Undergraduate Students. *Int Dent Educ* 2006;70:676- 80.
 9. Melrose RJ, Handlers JP, Kerpel S, Summerlin DJ, Tomich CJ. The use of biopsy in dental practice. The position of the American Academy of Oral and Maxillofacial Pathology. *Gen Dent* 2007;55:457-61.
 10. Kahn MA, Lynch DP, Turner JE, Mincer HH. The dos and don'ts of an oral mucosal biopsy performed by the general dentist. *J Tenn Dent Assoc* 1998;78:28-31.
 11. Zargarani M , Baghaei F , Moghimbeigi A , Shojaeian MS. Evaluation of Pre-analytical Biopsy Specimen Errors in the Pathology Laboratory of Hamadan School of Dentistry (2009-2010). *J Dent Shiraz Univ Med Scien* 2012;13:103-9.
 12. Pippi R. Technical notes about soft tissues biopsies of the oral cavity. *Minerva Stomatol* 2006;55: 551-66.
 13. Peña Torres LM, Revelo Pérez LA, Baños Aparicio G. Importance of biopsy in dental practice. *Pract Odontol* 1989;10:35-6.
 14. Jephcott A. The surgical management of the oral soft tissues: 3. Biopsy. *Dent Update* 2007;34: 654-7.
 15. Oliver RJ, Sloan P, Pemberton MN. Oral biopsies: methods and applications. *Br Dent J* 2004;196: 329–33.
 16. Gandolfo S, Carbone M, Carozzo M, Scamuzzi S. Biopsy technics in oral oncology: excisional or incisional biopsy? A critical review of the literature and the authors' personal contribution. *Minerva Stomatol* 1993;42:69-75.
 17. Brown RS, Bottomley WK, Abramovitch K, Langlais RP. Immediate biopsy versus a therapeutic trial in the diagnosis and treatment of vesiculobullous/vesiculoerosive oral lesions. Opposing viewpoints presented. *Oral Surg Oral Med Oral Pathol* 1992;73:694-7.
 18. Wooltorton E. Patients receiving intravenous bisphosphonates should avoid invasive dental procedures. *CMAJ* 2005; 172: 1684-8.
 19. Zargarani M , Baghaei F. A Review of Bisphosphonates and Bisphosphonate-related Osteonecrosis of the Jaw. *J Dent Shiraz Univ Med Scien* 2011;12:376-87.
 20. Siddiqi A, Payne AG, Zafar S. Bisphosphonate-induced osteonecrosis of the jaw: a medical enigma? *Oral Surg Oral Med Oral Pathol Oral Radiol Endod* 2009;108:1-8.
 21. Marx RE, Sawatari Y, Fortin M, Broumand V. Bisphosphonate-induced exposed bone (osteonecrosis/osteopetrosis) of the jaws: risk factors, recognition, prevention, and treatment. *J Oral Maxillofac Surg* 2005;63:1567-75.
 22. Rosai J. Rosai and Ackermans. *Surgical Pathology*. St. Louis: Mosby, 2004.
 23. Bramley PA, Smith CJ. Oral cancer and precancer: establishing a diagnosis. *Br Dent J* 1990;168:103-7.
 24. Shklar G. The effect of manipulation and incision on experimental carcinoma of hamster buccal pouch. *Cancer Res* 1968;28:2180-2.
 25. Harahap M. How to biopsy oral lesions. *J Dermatol Surg Oncol* 1989; 15: 1077-80.
 26. Eisen D. The oral mucosal punch biopsy. A report of 140 cases. *Arch Dermatol* 1992;128:815-7.

27. Lynch DP, Morris LF. The oral mucosal punch biopsy: indications and technique. *J Am Dent Assoc* 1990;121:145-9.
28. Allen CM. The oral pathology report: submission of specimens and interpretation of results. *Dermat Ther* 2002;15:179-84.
29. Reichart PA, Philipsen HP. Color atlas of dental medical oral pathology. New York: Thieme stuttgart, 2000.
30. Seoane J, Varela-Centelles PI, Ramirez JR, Cameselle-Teijeiro J, Romero MA. Artifacts in oral incisional biopsies in general dental practice: a pathology audit. *Oral Diseases* 2004;10:113-7.
31. Poh CF, Ng S, Berean KW, Williams PM, Rosin MP, Zhang L. Biopsy and histopathologic diagnosis of oral premalignant and malignant lesions. *J Can Dent Assoc* 2008;74:283-8.
32. Meghana SM, Ahmedmujib BR. Surgical artifacts in oral biopsy specimens: Punch biopsy compared to conventional scalpel biopsy. *J Oral Maxillofac Pathol* 2007;11:11-4.
33. Abbey LM, Sweeney WT. Fixation artifacts in oral biopsy specimens. *Va Dent J* 1972;49:31-4.
34. Sharif MA, Mushtaq S, Mamoon N, Jamal S, Luqman M. Clinician's Responsibility in pre-analytical quality assurance of histopathology. *Pak J Med Sci* 2007;23:720-3.

Corresponding Author:

Massoumeh Zargaran

Faculty of Dentistry

Hamadan University of Medical Sciences, Hamadan, Iran

Tel: +988118381063

Fax: +988118381085

E-mail: mm.zargaran@yahoo.com & massoumehzargaran@gmail.com