

Using Absorbable Gelatin Sponge to Facilitate Sinus Membrane Elevation during Open Sinus Lift: Technical Notes and Case Series

Sahand Samieirad^{1,2}, Majid Eshghpour³, Elahe Tohidi⁴, Anahid Jouya⁵,
Rashid Soufizadeh⁶, Hamed Kermani⁷

¹Dental Research Center, Mashhad University of Medical Sciences, Mashhad, Iran

²Oral & Maxillofacial Diseases Research Center, Mashhad University of Medical Sciences, Mashhad, Iran

³Associate Professor, Oral and Maxillofacial Surgery Department, Mashhad Dental School, Mashhad University of Medical Sciences, Mashhad, Iran

⁴Oral and Maxillofacial Radiologist, Oral And Maxillofacial Diseases Research Center, Mashhad University of Medical Sciences, Mashhad, Iran

⁵Student, Student Research Committee, Mashhad Dental School, Mashhad University of Medical Sciences, Mashhad, Iran

⁶Post Graduate of Oral And Maxillofacial Surgery, Mashhad Dental School, Mashhad University of Medical Sciences, Mashhad, Iran

⁷Craniofacial and Pediatric Maxillofacial Surgery Fellow, Oral and Maxillofacial Surgery Department, Tehran University of Medical Sciences, Tehran, Iran

Received 22 May 2018 and Accepted 31 August 2018

Abstract

Ridge atrophy accompanied by the pneumatization of maxillary sinus in the maxillary posterior region may lead to inadequate bone height, thereby precluding implant placement. Therefore, it may be mandatory to perform a sinus membrane elevation procedure and augmentation in the bone. The present study aimed to introduce a novel modification method for sinus floor elevation using a gelatin sponge (Gelatamp, COLTÈNE ROEKO, India) in order for better visualization, hemostasis, and conservative maxillary sinus membrane dissection with the low risk of complications. Implant placement was performed in a case series of 28 patients with hyperpneumatized sinus or a moderately resorbed posterior maxillary alveolus.

According to the findings, implant placement caused no complications in the patients. Furthermore, none of the patients experienced infections, sinusitis or graft and implant failure clinically and radiographically at the three- and six-month follow-up. Therefore, it

could be concluded that gelatamp-assisted sinus lift is a simple, safe, noninvasive, and innovative technique for sinus membrane elevation. In addition, it is predictable and efficient, especially in the cases where piezoelectric surgery armamentarium is not available.

Keywords: Sinus Lift, Gelatin Sponge, Implant.

Samieirad S, Eshghpour M, Tohidi E, Jouya A, Soufizadeh R, Kermani H. Use of Absorbable Gelatin Sponge to Facilitate Sinus Membrane Elevation during Open Sinus Lifting: Technical Note and Case Series. J Dent Mater Tech 2019; 8(1): 1-7.

Introduction

Long-term edentulism in the maxillary posterior region often leads to the resorption of the alveolar process. Simultaneously, the maxillary sinus is pneumatized, and the remaining bone volume in the maxillary posterior region may not suffice (1-3). Clinicians and researchers have constantly attempted to develop new techniques to overcome this challenge and use dental implants for the replacement of missing teeth (1-6).

Sinus elevation is a surgical procedure that is performed to increase the bone volume in the maxillary sinus floor in order to enable the installation of implant fixtures, especially when the initial height of the alveolar bone cannot ensure the primary stability of the implants that are placed simultaneously (1, 2, 5).

The elevation of the maxillary sinus membrane and its grafting with bone substitutes have become a routine practice over the past 40 years (1). The lateral window approach is commonly used for maxillary sinus augmentation. In this technique, a bone window is generated in the lateral wall of the maxilla, through which the Schneiderian membrane is dissected from the alveolar process of the maxilla and pushed upward. Following that, the newly-formed space is filled with grafting material so as to maintain space for the formation of the new bone, which results in the favorable conditions for implant insertion (1, 2, 5).

Several studies have documented the technical details of the lateral window approach, and the procedures have shown clinical predictability (1-9). It is also notable that the dissection of the Schneiderian membrane from the sinus floor is technically difficult, and perforation could occur if the membrane is thin or in the presence of bone septa. Previous findings have indicated the frequency of this complication to be 58% (1-3, 7).

The present study aimed to introduce a novel modification method for sinus floor elevation using gelatin sponge (gelatamp) for better visualization, hemostasis, and conservative maxillary sinus membrane dissection with the low risk of the associated complications in order to increase vertical bone height for implant placement in a case series of the patients with hyperpneumatized sinus or moderately resorbed posterior maxilla.

Gelatamp is a hemostatic, absorbable, and inexpensive material, which is available in most clinics (8, 10). Gelatin sponge reflects the sinus membrane bluntly and gently with a minimal risk of membrane perforation. Moreover, it serves as a sinus defect volume indicator for the assessment of the required bone graft volume. This simple, safe, and noninvasive sinus lift technique could contribute to sinus membrane elevation more predictably, especially in the cases where the piezoelectric surgery armamentarium is not available.

Report of Cases and Technique

During September 2015-June 2017, 28 patients underwent open sinus lift surgery at the Oral and Maxillofacial Department of the School of Dentistry in Mashhad, Iran to receive sinus membrane elevation. The patients with hyperpneumatized sinus or moderately resorbed posterior maxilla were enrolled in the study.

The exclusion criteria of the study were the history of chronic maxillary sinus infection, pansinusitis or addiction. The present study was conducted in accordance with the Declaration of Helsinki, and the protocol was approved by the Institute of Human Research and Ethics Committee of Mashhad University of Medical Sciences (IR.MUMS.sd.1394.89).

Surgical Technique

Prophylactic oral antibiotic capsules (600 mg of clindamycin) were administered to the patients one hour before the surgery. The surgery was performed with local maxillary block anesthesia using 2% lidocaine and 1:100,000 epinephrine.

Intraoral access to the maxillary sinus was achieved through the oral mucosa of the anterior maxillary sinus wall. Maxillary sinus floor elevation was carried out using the lateral approach on all the patients. The approach to the lateral wall of the maxillary sinus was adopted after the elevation of a mucoperiosteal flap based on the surgical requirements of the patients. A medium-sized round diamond bur was attached to a straight hand piece, which was used with copious saline irrigation in order to develop a lateral window through the maxillary sinus.

The anterior vertical osteotomy was placed at two millimeters distal to the anterior vertical wall of the

maxillary sinus, and the distal osteotomy was placed at approximately 20 millimeters from the anterior vertical osteotomy. The height of the vertical osteotomy was approximately 10 millimeters. The anterior and inferior osteotomy lines were perpendicular to the internal surface of the lateral wall of the maxillary sinus, and the superior and posterior osteotomies were performed perpendicularly to the sinus wall.

The mentioned osteotomy design facilitated the accurate replacement of the bony window as a barrier over the future bone graft particles in the maxillary sinus. The bony window was meticulously detached so as to expose the sinus membrane. In the first stage, part of the Schneiderian membrane was cautiously dissected from the sinus floor and walls using a flat, blunt-edged sinus elevator curette.

In the following stage, the absorbable gelatin sponge (Gelatamp, COLTÈNE ROEKO, India) was employed in the second phase of noninvasive sinus lift. Afterwards, the dry gelatamp sponge was placed on the sinus floor with slight pressure using Adson forceps. The dry brown gelatamp sponge was used in this method in order to exert the effective force for the complete elevation of the remaining Schneiderian membrane from the maxillary sinus floor similar to surgical gauze dissection. Dissection of the sinus membrane continued bluntly and gently so as to be reached and reflected off the medial and posterior walls of the sinus cavity.

When the sinus membrane was adequately reflected, the gelatamp sponge remained in the maxillary sinus for 5-15 minutes. Resorbing the liquids, the sponge becomes mechanically weak; nevertheless, it effectively contributes to hemostasis. On the other hand, the size and number of the applied gelatamp sponges help surgeons assess the volume of the free space requiring graft material for sinus augmentation. Although gelatin sponges resorb liquids and shrink, the volume of wet sponges could estimate the total size of the defect. Furthermore, the sponge on the sinus membrane exerts protecting effects to avoid membrane injuries or perforation during implant drilling.

Figure 1 depicts the schematic view of the gelatamp-assisted open sinus lift procedure.

After the completion of implant drilling and before implant placement, the gelatin sponge was removed. An absorbable collagen membrane (Jason Membrane,

Botiss Biomaterial GmbH, Germany) was placed directly above the cavity below the elevated sinus membrane in order to support the Schneiderian membrane. The cavity was passively filled with bone graft substitute (Cerabone, Botiss Biomaterial GmbH, Germany) before implant insertion, and the lateral wall of the augmented defect subsequently.

Figure 2 shows the clinical procedure of the gelatamp-assisted open sinus lift procedure.

The bony portion of the lateral window was repositioned to prevent soft-tissue in-growth into the sinus cavity and promote the formation of the new bone from the lateral wall of the maxillary sinus. Flaps were sutured using interrupted mattress sutures (Vicryl, Johnson, and Johnson, UK) in order to achieve passive primary closure.

The patients were instructed not to blow their nose for two weeks after the surgery and avoid coughing or sneezing with an open mouth. Preoperative prophylactic antibiotic treatment continued for seven days postoperatively (150 mg of clindamycin), and the sutures were removed 14 days after the surgery. After sinus augmentation, postoperative panoramic radiographs and cone-beam computed tomography (CT) scans were obtained. An average of six months was considered to all the integration of the implants.

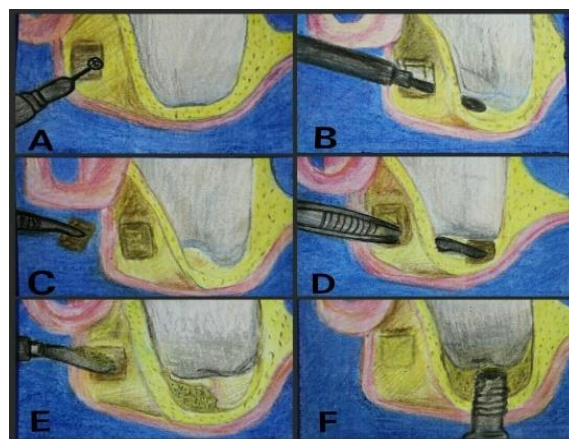


Figure 1. Schematic View of Gelatamp-assisted Open Sinus Lift Procedure; A) Lateral Window Preparation by Round Diamond Bur; B) Initial Dissection of Sinus Membrane Using a Periosteal Elevator; C, D) Final Sinus Membrane Dissection Using Gelatamp; E, F) Bone Graft and Implant Insertion

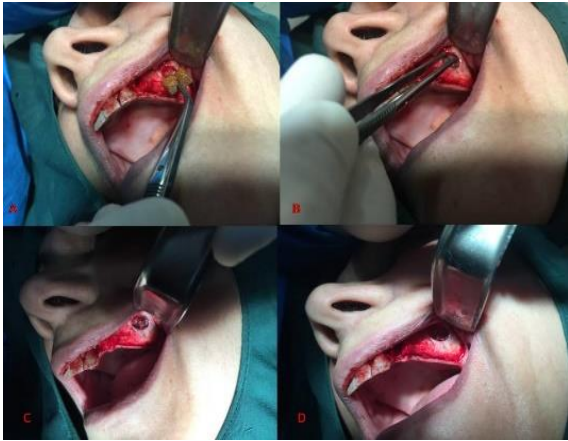

Figure 2. Clinical illustration of Gelatamp-assisted sinus lift procedur

Result

During September 2015-June 2017, sinus lift surgeries were performed on 28 patients (10 females

and 18 males) aged 38-68 years (mean age: 52 years). Diagnoses were confirmed through clinical examination, CT-scan, and panoramic imaging. According to the findings, the mentioned techniques caused no complications in the patients. In addition, none of the patients experienced infections, sinusitis, and graft or implant failure clinically or radiographically at the three- and six-month follow-ups.

Imaging evaluations confirmed that the sinuses were lifted and augmented effectively. Figures 3 and 4 illustrate the radiographic examination of the patients undergoing gelatamp-assisted sinus lift procedure with or without simultaneous implant placement. All the patients were referred to a prosthodontist six months after the surgery, and the implants were loaded without any complications.

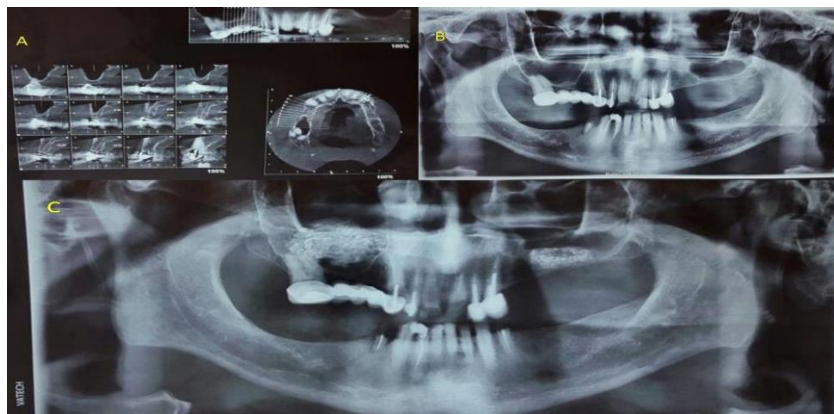


Figure 3. Radiographic Examination of a Patient Undergoing Gelatamp-assisted Sinus Lift Procedure without Simultaneous Implant Placement; A, B) Pre-operative CBCT and Panoramic View; C) Post-operative Panoramic View

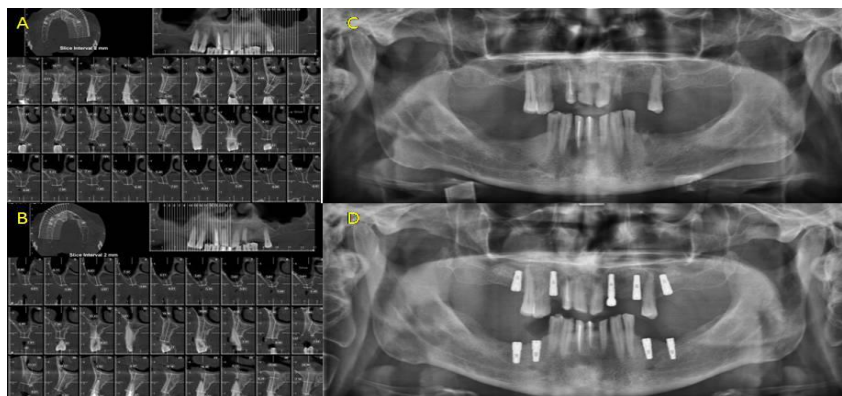


Figure 4. Radiographic Examination of a Patient Undergoing Gelatamp-assisted Sinus Lift Procedure with Simultaneous Implant Placement; A,B, C) Pre-operative CBCT and Panoramic View; D) Post-operative Panoramic View

Discussion

In the maxillary posterior region, residual ridge resorption is accompanied by the pneumatization of the maxillary sinus. This phenomenon leads to the lack of adequate bone quantity and quality, which further complicates implant placement (1, 2, 4). The most common technique to overcome these complications is sinus membrane lift procedure and augmentation of the maxillary sinus floor (1, 2, 4, 6). The classic technique was introduced by Tatum and further modified by Boyne and James (9).

Studies with long-term follow-ups have proposed satisfactory results regarding implant survival using two common techniques, including lateral sinus floor elevation (open sinus lift) and the osteotome technique (closed sinus lift) (1-4). For instance, a meta-analysis by Pjetursson et al. (5) reviewed 48 studies with 12,020 placed implants in 4,000 patients, and the findings indicated that the three-year implant survival rate was 90.1% after lateral sinus augmentation.

Several minor variations and modifications have been demonstrated in open sinus lift surgery to dominate the associated challenges (1-9). Correspondingly, the most common issue during direct sinus elevation has been the perforation of the membrane due to the presence of septa or a slim membrane (1-3, 7). The septa in the maxillary sinus are more frequently detected in partially edentulous patients compared to dentate and completely edentulous patients. In addition, the most common location of the septa has been reported to be the middle region of the maxillary sinus (1-3, 7).

Gelatin sponge (gelatamp) is a hemostatic, absorbable, and inexpensive packing substance. It is also a water-insoluble, non-elastic, porous, and pliable material prepared from purified pork-skin gelatin, which can absorb fluids completely with slight tissue reaction and does not require removal unlike non-absorbable substances (4, 8, 10, 11). Gelatamp was introduced in the 1940s by Dr. Gray to be used in neurosurgical procedures (10, 13).

The sponge is routinely applied in oral and maxillofacial surgeries for the control of bleeding after dental extraction, removal of small cysts, biopsies, and management of dry socket (alveolar osteitis) (2, 11). Moreover, it is used to reduce bleeding and stabilize the blood clot to achieve local hemostasis, especially when conventional methods are not sufficient to control bleeding.

The porous structure of gelatamp allows the product to have a high capacity for fluid absorption. It also contributes to the formation of blood clot through activating the cascade of coagulation factors and inducing platelet agglutination in the case of bleeding. Practically, gelatamp acts as a matrix and adds further reinforcement to the formed blood clot (4, 8, 12). This material has also been used as a protective agent against the surgical wounds occurring during dental surgical procedures, such as periodontal surgery, grafting, and maxillary sinus surgeries (11-14).

Several studies have documented the efficacy of gelatamp in hemostasis and wound healing after frontal sinus repair and functional endoscopic sinus surgery (FESS) (4, 10, 15). Furthermore, the combination of gelatamp and rhBMP-2 has been used successfully as a graft material in maxillary sinus floor augmentation in sheep. The combination of rhBMP-2 and a collagen sponge matrix has proven promising as a therapeutic approach in various applications. For instance, it could enhance bone repair in spine surgery, as well as bone fractures and craniofacial surgeries (1, 8, 14, 16).

Gelatamp has been shown to be a more effective hemostatic agent compared to other packing materials. Several clinical trials have suggested that gelatamp is biocompatible and efficient for use in chronic otitis media surgery and FESS without any complications. However, using the sponge in contaminated or infected areas is not recommended (2, 4, 10, 16). Gelatamp is gradually absorbed by phagocytosis within 4-6 weeks. The absorption could be influenced by several factors,

including the amount of the applied material, degree of saturation with blood or other fluids, and site of use (8, 10).

In a research in this regard, Marx and Garg (2002) reported the use of cottonoid soaked in 2% lidocaine with 1:100,000 epinephrine (one cartridge) for the elevation of the sinus membrane in sinus lift procedures. In the mentioned study, the key advantage of the substance was vasoconstriction and hemostasis properties (6).

In the present technical note, the application of gelatamp was observed to have numerous advantages compared to the conventional sinus lift methods, simplifying and facilitating the procedure to be more conservative. In the first step, part of the Schneiderian membrane was meticulously dissected from the sinus floor and walls using a flat, blunt-edged sinus elevator curette. Following that, the absorbable gelatin sponge was used in the second step of the noninvasive sinus lift method. At this stage, the dry gelatamp sponge was placed on the sinus floor with slight pressure using Adson forceps in the final stage. The sponge helped reflect the sinus membrane bluntly and gently with a minimal risk of membrane perforation. We used a dry, brown gelatamp sponge in this method in order to exert force for the complete elevation of the remaining Schneiderian membrane from the maxillary sinus floor, which is similar to surgical gauze dissection.

The sponge could also reduce oozing and bleeding through hemostasis. On the other hand, the gelatamp-assisted technique enhanced the direct visualization of the maxillary sinus cavity and membrane via arresting the oozing type of bleeding from the sinus membrane and maxillary sinus floor. There are numerous other advantages to this technique. For instance, it enables surgeons to estimate the volume of the free space requiring graft material for sinus augmentation based on the size and number of gelatamp sponges. Therefore, it serves as a volume indicator to determine the bone graft volume required for effective augmentation.

Although gelatin sponges resorb liquids and may shrink, the defect size could be properly verified based on the volume of wet sponges. Resorbing liquids, the sponge becomes mechanically weak; nevertheless, it effectively contributes to hemostasis. Furthermore, gelatamp prevents membrane injuries and perforation through overlying the sinus membrane, acting as a protecting agent during implant drilling.

Gelatamp-assisted sinus lift technique is simple, noninvasive, and safe, while making sinus membrane elevation more predictable, especially in the cases where piezoelectric surgery armamentarium is not available.

Conclusion

Gelatamp-assisted sinus lift is a new and safe approach to gentle, conservative sinus floor membrane elevation, which is associated with minimal intraoperative complications in the patients with hyperpneumatized maxillary sinus or moderately resorbed posterior maxilla. Through arresting the oozing from the sinus membrane and maxillary sinus floor, gelatamp-assisted technique could enhance the direct visualization of the maxillary sinus cavity during lifting.

Conflict Interests

The authors declare that there is no conflict of interests regarding the publication of this paper.

References

1. Hegde R, Prasad K, Shroff KK. Maxillary sinus augmentation using sinus membrane elevation without grafts-A Systematic Review. *J Indian Prosthodont Soc.* 2016;16(4):317-322.
2. Riben C, Thor A. The maxillary sinus membrane elevation procedure: augmentation of bone around dental implants without grafts—a review of a surgical technique. *Int J Dent.* 2012: 1-9.
3. Hatano N, Sennerby L, Lundgren S. Maxillary Sinus Augmentation Using Sinus Membrane Elevation and Peripheral Venous Blood for Implant-Supported Rehabilitation of the Atrophic

- Posterior Maxilla: Case Series. *Clin Implant Dent Relat Res* 2007;9(3):150-155.
4. Sohn D-S, Moon J-W, Moon K-N, Cho S-C, Kang P-S. New bone formation in the maxillary sinus using only absorbable gelatin sponge. *J Oral Maxillofac Surg.* 2010; 68(6): 1327-1333.
 5. Pjetursson BE, Tan WC, Zwahlen M, Lang NP. A systematic review of the success of sinus floor elevation and survival of implants inserted in combination with sinus floor elevation. *J Clin Periodontol.* 2008; 35(s8):216-240.
 6. Marx RE, Garg AK. A novel aid to elevation of the sinus membrane for the sinus lift procedure. *Implant Dent.* 2002;11(3):268-271.
 7. Simunek A, Kopecka D, Cierny M. The use of oxidized regenerated cellulose (Surgicel®) in closing Schneiderian membrane tears during the sinus lift procedure. *West Indian Med J.* 2005;54(6):398-399.
 8. Geiger M, Li R, Friess W. Collagen sponges for bone regeneration with rhBMP-2. *Adv Drug Deliv Rev.* 2003;55(12):1613-1629.
 9. Boyne PJ, James RA. Grafting of the maxillary sinus floor with autogenous marrow and bone. *J Oral Surg (American Dental Association: 1965).* 1980;38(8) :613-616.
 10. Wee JH, Lee CH, Rhee CS, Kim J-W. Comparison between Gelfoam packing and no packing after endoscopic sinus surgery in the same patients. *Eur Arch Otorhinolaryngol.* 2012;269(3):897-903.
 11. Scarano A, Murmura G, Di Cerbo A, Palmieri B, Pinchi V, Mavriqi L, et al. Anti-hemorrhagic agents in oral and dental practice: an update. *Int J Immunopathol Pharmacol.* 2013; 26(4): 847-854.
 12. Higuchi T, Kinoshita A, Takahashi K, Oda S, Ishikawa I. Bone regeneration by recombinant human bone morphogenetic protein-2 in rat mandibular defects. An experimental model of defect filling. *J Periodontol.* 1999;70(9):1026-1031.
 13. Kinoshita A, Oda S, Takahashi K, Yokota S, Ishikawa I. Periodontal regeneration by application of recombinant human bone morphogenetic protein-2 to horizontal circumferential defects created by experimental periodontitis in beagle dogs. *J Periodontol.* 1997;68(2): 103-109.
 14. Kawakatsu N, Oda S, Kinoshita A, Kikuchi S, Tsuchioka H, Akizuki T, et al. Effect of rhBMP-2 with PLGA/gelatin sponge type (PGS) carrier on alveolar ridge augmentation in dogs. *J Oral Rehabil.* 2008;35(9):647-655.
 15. Zhou H-J, Zhan R-Y, Zheng X-J, Li G, Cao F, Chen M-T. Use of medical aural and encephalic glue-soaked gelfoam for frontal sinus repair: A single-centre experience. *J Craniomaxillofac Surg.* 2013;41(7):665-669.
 16. Gutwald R, Haberstroh J, Stricker A, Rütther E, Otto F, Xavier SP, et al. Influence of rhBMP-2 on bone formation and osseointegration in different implant systems after sinus-floor elevation. An in vivo study on sheep. *J Craniomaxillofac Surg.* 2010;38(8):571-579.

Corresponding Author

Hamed Kermani
 Craniofacial and Pediatric Maxillofacial Surgery Fellow,
 Oral and maxillofacial surgery department,
 Tehran University of Medical Sciences Dental School, Tehran, Iran.
 Tel: 00989128361094
 Fax: 00982188015880
 Email: hamedkermani1980@gmail.com